



Ultrasound-Guided Versus Blind Mandibular Nerve Blocks in Goats:

A Clinical Trial



Mohamed W. El-Sherif* and Mohamed A. Abdelkawi

Department of Surgery, Faculty of Veterinary Medicine, New Valley University, El-Kharga, New Valley, 25711 Egypt.

Abstract

IN goats, regional nerve blocks are preferred over general anesthesia because of their safety and cost-effectiveness. Mandibular nerve blocks are essential for managing dental, endodontic, and periodontal issues, fractures, and mandibular tumors. Ultrasound guided blocks provide real-time visualization and precise needle guidance. The aim of this study is to compare the ultrasound-guided mandibular nerve block technique with the blind technique. In a clinical trial involving 24 adult goats were used. Twenty-four blind mandibular nerve blocks based on the anatomical landmarks were randomly performed on one side of the mandible. Ultrasound guided blocks were performed in the other random 24 trials. The results showed that ultrasound guided approach was significantly more efficient, taking (3.2 ±1.7) minutes to locate the mandibular foramen compared to (11.03 ±0.73) minutes in blind blocks trials. Ultrasound guided blocks achieved anesthesia onset in just (1.57 ±0.35) minutes, while blind blocks took (2.8 ±0.34) minutes. Furthermore, ultrasound-guided blocks showed maintenance of anesthesia for a longer duration (88.1 ±6.9 min) than blind approach (80.9 ±7.4 min). In blind approach, three trials failed to achieve anesthesia because of localization difficulties, highlighting the challenges of blind techniques. In conclusion, ultrasound-guided mandibular nerve block offers clear advantages over blind techniques in terms of feasibility, efficiency, and accuracy.

Keywords: Goat, Extraoral, Nerve block, Mandibular nerve, Ultrasound guided.

Introduction

The mandibular nerve, also referred to as the inferior alveolar nerve, is a branch of the trigeminal nerve responsible for supplying sensory innervation to the lower jaw [1]. Mandibular nerve block is an effective method for achieving analgesia during various procedures involving the mandible, dentition, periodontal and endodontic procedures, and jaw fracture repair [1–3]. In both small and large animal practice, a range of methods for mandibular nerve block have been established, encompassing both extraoral and intraoral approaches [4–9]. However, conventional techniques that rely on anatomical landmarks may present significant challenges owing to the inherent variations in anatomical structure [10]. Ultrasound guidance has emerged as a valuable tool to address these challenges. This approach provides real-time visualization of the target nerve and its surrounding anatomical structures, significantly enhancing the precision of nerve block [11,12].

Ultrasound-guided nerve blocks in animals offer numerous advantages, including enhanced precision and accuracy, reduced complications, and the use of lower anesthetic dosages. By providing real-time visualization of the nerve and surrounding structures, this technique minimizes the risk of inadvertent tissue damage and improves overall safety [11]. The procedure typically results in higher success rates, quicker onset of anesthesia, and reduced procedure time, contributing to greater efficiency. Additionally, it enhances animal comfort by decreasing the need for multiple needle insertions [12]. In human medicine, the extraoral block technique entails identifying the pterygomandibular space situated between the coronoid process and condyle of the mandible through ultrasound imaging. Subsequently, the needle is guided to a precise location near the maxillary artery, facilitating the administration of anesthetic agents [13–15]. The primary objective of this study was to provide a comprehensive evaluation of extraoral ultrasound-guided mandibular nerve block versus blind block in local breed goats.

*Corresponding authors: Mohamed W. El-Sherif, E-mail: mohamedelsherif@vet.nvu.edu.eg, Tel.: +201008467944

(Received 24 April 2024, accepted 27 July 2024)

DOI: 10.21608/EJVS.2024.285052.2036

©National Information and Documentation Centre (NIDOC)

Material and Methods

Goat selection and preparation

Twenty-four adult female Egyptian local goats (*Capra hircus*) with a mean age of 18.0 ± 1.3 months and a mean weight of 39.4 ± 1.2 kg were included in this study. A priori power analysis determined the sample size. Two blocking procedures, blind block and ultrasound-guided block were randomly assigned to the left or right mandible of each goat. To avoid potential analgesic masking, chemical restraint medications were not employed. For consistency, a single surgeon performed all procedures. A separate veterinary surgeon conducted blinded assessments, and all measurements were recorded. For all 48 procedures, goats were restrained in a standing position with their heads securely held by an assistant. The assistant tilted the head upward and laterally exposed the intermandibular and throat regions. The needle insertion site was thoroughly prepared and touched with chlorhexidine antiseptic solution (Cyteal, MUP, Egypt). Finally, three 70% alcohol swabs were applied. A 0.5 ml subcutaneous bleb of 1% lidocaine (Lidocaine, Hospira Inc. USA) was administered for local anesthesia at the needle insertion site.

Blind Mandibular Nerve Block

In the block group (n=24), 24 blind mandibular nerve blocks were performed with random allocation to the left or right mandible of each goat. Anatomical landmarks described by Dalga (2021) alongside self-searching guided the procedure. The surgeon used their index finger to locate the ipsilateral mandibular foramen by applying pressure to the caudal medial aspect of the mandibular ramus, palpating through the skin and medial pterygoid muscle until the foramen's depression was identified. The surgeon then stabilized the foramen with their non-dominant hand while slowly inserting a 20 G, 90 mm spinal needle between the medial surface of the mandible and the medial pterygoid muscle using the dominant hand. The needle advanced until it reached the previously identified depression. The surgeon removed his non-dominant hand, checked for vascular puncture through aspiration, and, if none was found, 2 ml of lidocaine HCl solution (lidocaine 0.5%, Hospira Inc., USA) injected into the target site. Finally, the needle was gradually withdrawn.

Ultrasound-guided mandibular nerve block

In this group (n=24), a micro curved array high-frequency ultrasound probe (Edan DUS 60, 9.4 MHz, Edan, China) was used to visualize and allocate the mandibular nerve. Goats were restrained in a standing position, and their heads were stabilized in an upward and lateral position by an assistant. Prior to examination, a thick layer of ultrasound coupling gel was applied to the intermandibular area. The ultrasound transducer was positioned 2.5 cm

cranially to the caudal border of the mandibular ramus, perpendicular to the mylohyoid muscles at the floor of the intermandibular space. Slight transducer tilting optimized visualization of the inferior alveolar nerve as a hypoechoic spherical structure directly imposed on the medial surface of the mandible. A 20G, 90 mm spinal needle was then percutaneously inserted and carefully advanced under ultrasonographic guidance until it reached the nerve location. Subsequently, 2 ml of 0.5% lidocaine HCl solution (Lidocaine, Hospira Inc., USA) was injected, and the needle was withdrawn (Fig.1).

Assessment and Data Collection

Feasibility of the procedure was defined as the assessment of whether the procedure can be realistically and effectively carried out given the available resources, circumstances, and constraints. The onset of local anesthesia is defined as the time it takes for the anesthetic agent to begin absence of sensation to the target area. Objective pain evaluation tests included behavioral measures such as vocalization, lip-licking, teeth-gnawing, ear posture, reaction to the environment, social isolation, feeding behavior, abnormalities in gait, righting reflex, limping [1-3] and pin-prick testing as direct and indirect signs of pain sensation. A standardized method of pin-prick involves use of 1 ml insulin syringe. This ensures that the same amount of pressure is applied to both the affected (mandible) and the control sites (maxilla). If goat reports exaggerated pain in the affected site this would suggest that hyperalgesia is present and vice versa [4]. Two levels of pin-prick test were utilized: superficial and deep were applied every 2 minutes to assess the degree and duration of analgesia. The duration of anesthesia was recorded from the initiation of analgesia until the goat showed pain manifestations. Efficacy was assessed by ability to apply deep insertion of the needle to the anesthetized mandibular mucosa without pain manifestation.

Data Analysis

The obtained values were reported as mean, and standard deviations. The independent *t-test* was used to carry out statistical analysis $p \leq 0.05$ was considered statistically significant. All obtained values were analyzed using the SPSS software (version 20.0; IBM, USA).

Results

The results revealed the superiority of ultrasound-guided nerve block group over the blind block group regarding feasibility of the procedure, onset of anesthesia, duration, and efficacy of the anesthesia (table 1).

Feasibility of the procedure

The obtained results showed significant difference between the two experimented groups (P=

0.005). In blind injection technique, localization of the mandibular foramen was not easy and was time consuming. The mean time needed to locate the mandibular foramen was 11.03 (± 0.73) minutes. In contrast, ultrasound guided injection technique displayed feasible localization of the mandibular nerve through extraoral ultrasound scanning (figure 2). The mean time needed for locating the mandibular nerve and foramen was 3.2 (± 1.7) minutes. Three trials in the blind-block technique (0.24%) failed to anesthetize the mandibular nerve. For the onset of anesthesia, excluding three trials, the mean onset time in blind block technique was (2.8 ± 0.34) minutes. In ultrasound guided technique, the mean onset time was (1.57 ± 0.35) minutes. The results demonstrated a significantly faster onset of anesthesia in the ultrasound-guided group than in the blind mandibular nerve block group ($P = 0.005$). Regarding the duration of anesthesia, excluding three failed trials, blind block technique exhibited a mean duration of (80.9 ± 7.4) minutes. Ultrasound guided block technique displayed a mean duration of (88.1 ± 6.9) minutes. There was a statistically significant difference between both groups ($P = 0.039$).

Area anesthetized

No anesthesia was detected in three trials in blind block approach. The other trials showed nonuniform varying degrees of analgesia of the mandible, mucous membrane of the ipsilateral cheek, and lateral border of the tongue. In ultrasound-guided block, there was a uniform analgesia of the ipsilateral mandible, mucous membrane, and lateral border of the tongue extended rostrally.

Discussion

The use of ultrasound-guided techniques in veterinary medicine has seen a growing trend owing to their precision and safety [3, 16, 21, 22]. One such application is ultrasound-guided mandibular nerve block, this technique is particularly valuable in mandibular procedures, where effective anesthesia is vital for successful surgery and pain management [23]. Our study results align with these recommendations, underscoring the feasibility, time efficiency, and accuracy of ultrasound-guided mandibular nerve block over the blind block technique. Blind localization of the mandibular nerve or a combination of anatomical landmarking and finger guidance for intraoral access to the mandibular foramen is a well-established technique in human medicine [24]. However, in this investigation, this method proved impractical because the papillae covered the mucosal surface. As a result, we adopted an approach combining anatomical knowledge, as reported by Dalga [16], and finger-guided searches, which proved to be more relevant. The results demonstrated the difficulty of localizing the foramen using finger-guided techniques, especially when goats are not sedated. This highlights the value of

ultrasound guidance in such cases. Clinically, sedation is recommended for both techniques according to the recommendations of anaesthesiologists [25]. The data revealed that ultrasound guidance had a significantly reduced time needed to locate the mandibular foramen compared to blind allocation. This reduction is attributed to the reduced effort needed to restrain the goats and the direct visualization of the nerve through ultrasound. Ultrasound guided blocks achieved anesthesia onset significantly faster, with a lower mean time than blind block. These results seem to be a result of precise allocation and injection nearby the nerve. Additionally, ultrasound guided block had a longer average duration of anesthesia than blind blocks, with a smaller standard deviation. These findings indicate precise injection sites in ultrasound guided blocks, contributing to the consistent and extended duration of anesthesia. The results of this study highlight the feasibility of using the ultrasound visualization window of the mandibular foramen with a micro convex array transducer through the intermandibular space. The endo-cavity head probe offers excellent handling to the operator, making needle adjustments optimal. Regional anesthetic techniques require a profound understanding of anatomical structures. Operators often face challenges in identifying precise anatomical landmarks, dealing with variations in the anatomy of peripheral nerves, and accounting for sex and individual differences [26]. Our study underscores the inadequacy of relying solely on anatomical landmarks, as in blind blocks, to apply anesthesia to all goats. Three trials in blind approach failed to get anesthetized. Also, blind techniques have been associated with the potential for inadvertent penetration of adjacent structures [27]. The ultrasound-guided approach described here provides real-time visualization of anatomical landmarks for precise localization, thereby reducing the incidence of faulty injections. These results emphasize the advantages of ultrasound guidance, leading to more efficient procedures, faster onset of anesthesia, and a longer and consistent duration of anesthesia compared to the blind mandibular nerve block method, especially when excluding cases of faulty needle insertion [12]. Owing to the complexity of assessing pain and the multitude of aspects and variants in the animal behaviour when they are suffering pain, further research is needed with more accurate pain assessment methods. Also, clinical procedures of the mandible after ultrasound guided block are needed for more accurate results.

Conclusion

In conclusion, the ultrasound-guided vertical extraoral approach enhances the visualization of anatomical landmarks and facilitates precise injection of local anaesthetic. Given that the experiment was conducted on ostensibly healthy animals, additional

research would be of substantial importance to investigate the ultrasound-guided mandibular block in sheep afflicted with clinical mandibular surgical conditions.

Acknowledgments

The authors would like to thank Dr. Mohamed Ramadan for his kind assistance and permission to perform this clinical study on his own goat farm.

Funding statement

This study didn't receive any funding support.

Declaration of Conflict of Interest

The authors declare that there is no conflict of interest.

Ethical of approval

This study was approved by the Institutional Animal Care and Use Committee of the Faculty of Veterinary Medicine of New Valley University (approval number: VM/NVU/23(1)-34). The study was conducted in strict accordance with ethical guidelines and regulations for the care and use of animals in research. Goats used in this study were obtained directly from their respected owner. In adherence to ethical standards, we confirmed that informed consent from the owner was obtained. All methods are reported in accordance with the ARRIVE guidelines (<https://arriveguidelines.org>). All animals have been accommodated and cared for according to the Egyptian animal welfare law (No. 53, 1966).

TABLE 1. Time elapsed to localize the nerve and onset and duration of anaesthesia.

	Group A			Group B			P value
	mean	SD	N	mean	SD	N	
Time to locate the nerve	11.03	0.74	12	3.2	1.75	12	0.005
Onset of anaesthesia	2.8	0.34	9	1.57	0.35	12	0.005
Duration of anaesthesia	80.99	7.44	9	88.15	6.96	12	0.039

* SD= standard deviation, N= number

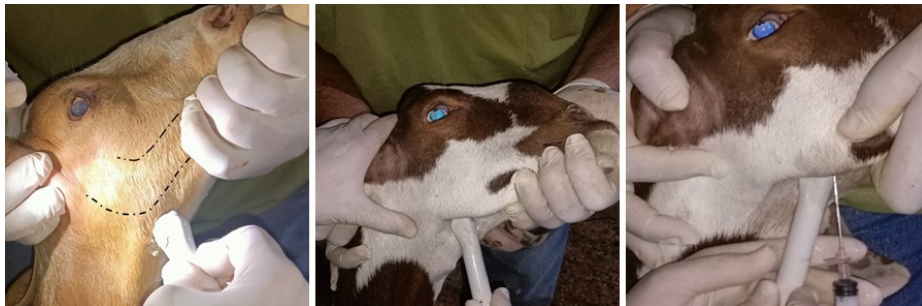


Fig. 1. Poisoning of the ultrasound transducer and spinal needle for ultrasound-guided mandibular.

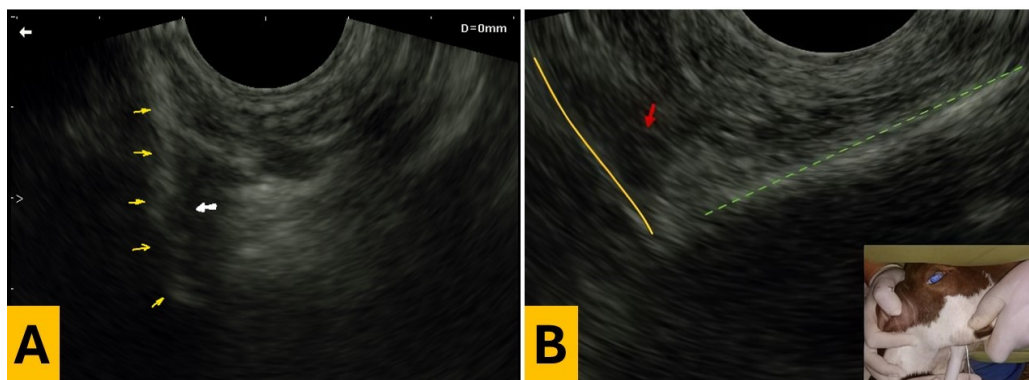


Fig. 2. (A) photograph showing the mandible as a hyperechoic line (yellow arrowheads) and the mandibular nerve as immersing into the mandibular foremen as a hypoechoic spherical structure (white arrowhead). (B) photograph showing the mandibular nerve (Red arrow), the mandible (Yellow line) and the spinal needle (green dotted line).

References

- Castejón-González, A.C. and Reiter, A.M. Locoregional Anesthesia of the Head. *Vet. Clin. North Am. Small Anim. Pract.*, **49**(6), 1041-1061 (2019).
- Henry, T., Pusterla, N., Guedes, A. G. and Verstraete, F. J. Evaluation and clinical use of an intraoral inferior alveolar nerve block in the horse. *Equine Vet. J.*, **46**(6), 706-710 (2014).
- Campoy, L. and Sedgwick, S.R. Standing Sedation and Iocoregional Analgesia in Equine Dental Surgery. *Vet. Clin. North Am. Equine Pract.*, **36**(3), 477-499 (2020).
- Tremaine, W.H., Local analgesic techniques for the equine head. *Equine Veterinary Education*, **19**(9), 495-503 (2007).
- O'Morrow, C. Advanced dental local nerve block anesthesia. *Can. Vet. J.*, **51**(12), 1411-1415 (2010).
- Edmondson, M.A., Local and regional anesthesia in cattle. *Vet. Clin. North Am. Food Anim. Pract.*, **24**(2), 211-226 (2008).
- Grubb, T. and Lobprise, H. Local and regional anaesthesia in dogs and cats: Descriptions of specific local and regional techniques (Part 2). *Vet. Med. Sci.*, **6**(2), 218-234 (2020).
- Nazih, M.A. and El-Sherif, M.W. Presentation of an intraoral approach for mandibular alveolar nerve block in cattle: Cadaveric study. *Scientific Journal of Animal Science*. **6**, 229-236 (2017).
- El-Sherif, M.W. and Nazih, M.A. A novel extraoral ultrasound-guided approach for mandibular nerve block in Rahmani sheep. *BMC Vet. Res.*, **20**(1), 74 (2024).
- Rochette, J. Regional anesthesia and analgesia for oral and dental procedures. *Vet. Clin. North Am. Small Anim. Pract.*, **35**(4), 1041-58, viii-ix (2005).
- Tran, D.Q., Muñoz, L., Russo, G. and Finlayson, R. J. Ultrasonography and stimulating perineural catheters for nerve blocks: a review of the evidence. *Can. J. Anaesth.*, **55**(7), 447-457 (2008).
- Re, M., Blanco-Murcia J., Villaescusa F., Gómez de Segura, A.I. and De Gaspar Simón I. A. Ultrasound-guided anaesthetic blockade of the pelvic limb in calves. *Vet. J.*, **200**(3), 434-439 (2014).
- Kampitak, W., Tansatit, T. and Shibata, Y. A Novel Technique of Ultrasound-Guided Selective Mandibular Nerve Block with a Lateral Pterygoid Plate Approach: A Cadaveric Study. *Reg Anesth Pain Med.* **43**(7), 763-767 (2018).
- Chanpong, B., Tang, R., Vaghadia, H. and Sawka, A. Novel technique of ultrasound-guided selective mandibular nerve block with a lateral pterygoid plate approach. *Reg Anesth Pain Med.*, **44**(3), 423 (2019).
- Cao, Z., Zhang, K., Hu, L. and Pan, J. Application of ultrasound guidance in the oral and maxillofacial nerve block. *Peer J.* **9**, 2543 (2021).
- Dalga, S. Applied anatomy to the Gurcu Goat's mandible in Kafkas and its clinical significance in regional anesthesia. *Turkish Journal of Veterinary Research*, **5**(2), 51-56 (2021).
- Ong, R.M., Morris, J. P., O'Dwyer, J. K., Barnett, J. L., Hemsworth, P. H. and Clarke, I. J. Behavioural and EEG changes in sheep in response to painful acute electrical stimuli. *Aust. Vet. J.*, **75**(3), 189-193 (1997).
- Mather, L.E., Cousins, M. J., Huang, Y. F., Pryor, M. E. and Barratt, S. M. Lack of secondary hyperalgesia and central sensitization in an acute sheep model. *Reg. Anesth. Pain Med.*, **25**(2), 174-180 (2000).
- Houfflin Debarge, V., Bresson, S., Jaillard, S., Elbaz, F., Riou, Y. and Dalmas, S. Development of a new model to investigate the fetal nociceptive pathways. *Fetal Diagn. Ther.*, **20**(5), 415-419 (2005).
- Callin, S. and Bennett, M.I. Assessment of neuropathic pain. Continuing Education in Anaesthesia Critical Care & Pain., **8**(6), 210-213 (2008).
- Salinas, F.V. Ultrasound and review of evidence for lower extremity peripheral nerve blocks. *Reg. Anesth. Pain Med.*, **35**(2 Suppl), S16-25 (2010).
- Re, M., Blanco, J. and Gómez de Segura, I.A. Ultrasound-Guided Nerve Block Anesthesia. *Vet Clin North Am. Food Anim. Pract.*, **32**(1), 133-147 (2016).
- Thieme, K., Mesquita, L., Lieberth, S., Dancker, C., Doherr, M. G. and Eule, J. C. Safety and accuracy of blind vs. ultrasound-guided dorsal retrobulbar nerve blocks in horses-A cadaveric study. *Vet. Ophthalmol.*, **26**(2), 135-144 (2023).
- Topazian, R.G. and Simon, G.T. Extraoral mandibular and maxillary block techniques. *Oral Surg Oral Med Oral Pathol.*, **15**, 296-300 (1962).
- Jones, R., Grimm, K.A., Lamont, L.L., Tranquilli, W.J., Greene, S.A. & Robertson S.A. (Eds.), Veterinary Anesthesia and Analgesia, Wiley Blackwell, 2015, ISBN: 9781118526231, 1072 pp.; - (hard). *The Veterinary Journal*, **206**, 93-99 (2015).
- Sundaram, V., Dharani, P., Gnanadevi, R. and Kavya, R. Studies on clinical anatomy of the maxillofacial and mandibular regions of the Madras Red sheep (*Ovis aries*) in India. *Folia Morphol (Warsz)*, **78**(2), 389-393 (2019).
- Aguilar-Catalan, A., Fresno Bermejo, L. and Murison, P.J. Continuous mandibular nerve block as sole analgesia for postoperative pain management after a hemimandibulectomy in a French Bulldog. *Veterinary Record Case Reports*, **10**(2), e308 (2022).

دراسة مقارنة لتخدير عصب الفك السفلي بالتوجيه بالموجات فوق الصوتية والطريقة التقليدية في الماعز

محمد وفقى الشريف* و محمد علي عبدالقوي

قسم الجراحة والتخدير والأشعة - كلية الطب البيطري- جامعة الوادي الجديد - مصر.

الملخص

في الأغنام، يفضل التخدير الموضعي والمنطقي على التخدير العام بسبب ارتفاع نسبة الأمان وفعاليتها ومن حيث انخفاض التكلفة. تُعتبر الحقن العصبية للعصب الفكي أساسية لإدارة الإصابات الجراحية في الأسنان وجذورها وجيوبها العظمية واللثة، والكسور، والأورام الفكية. توفر طريقة الحقن الموجهة بالموجات فوق الصوتية رؤية في الوقت الحقيقي وتوجيهاً دقيقاً للإبرة. تقارن هذه الدراسة بين تقنية الحقن العصبي الموجه بالموجات فوق الصوتية وتقنية الحقن العمياء التقليدية. شارك في التجربة السريرية 24 من الأغنام البالغة. أُجريت 24 حقنة عمياء للعصب الفكي السفلي على أساس العلامات التشريحية بشكل عشوائي على جانب واحد من الفك السفلي. وأُجريت الحقن الموجهة بالموجات فوق الصوتية في 24 تجربة أخرى بشكل عشوائي. أظهرت النتائج أن النهج الموجه بالموجات فوق الصوتية كان أكثر فعالية بشكل ملحوظ، حيث استغرق تحديد فتحة الفك السفلي (1.7 ± 3.2) دقيقة مقارنةً بـ (0.73 ± 11.03) دقيقة في تجارب الحقن العمياء. كما بلغت فترة بدء التخدير في الحقن الموجه بالموجات فوق الصوتية (0.35 ± 1.57) دقيقة، بينما استغرقت التجارب العمياء (0.34 ± 2.8) دقيقة. علاوةً على ذلك، أظهرت الحقن الموجهة بالموجات فوق الصوتية الحفاظ على التخدير لمدة أطول (6.9 ± 88.1) دقيقة مقارنةً بالنهج العمياء (7.4 ± 80.9) دقيقة. في النهج العمياء، فشلت ثلاث تجارب في تحقيق التخدير بسبب صعوبات التحديد، مما يبرز تحديات التقنيات العمياء. في الختام، يُقدم الحقن العصبي الموجه بالموجات فوق الصوتية مزايا واضحة على التقنيات العمياء من حيث الجدوى والكفاءة والدقة.

الكلمات الدالة: الماعز ، الموجات فوق صوتية ، التخدير ، العصب الفكي.