



Assessment of Essential Oils Treatment of Neem Extract Versus Ivermectin Against *Sarcoptes scabiei* In Rabbit Flocks



Osama G. Sakr¹, Hasna Thabit² and Marwa M. Attia³

¹Animal Production Department, Faculty of Agriculture, Cairo University, 12613, Giza, Egypt.

²Department of Zoology and Entomology, Faculty of Science, Assiut University, 71526, Assiut, Egypt.

³Department of Parasitology, Faculty of Veterinary Medicine, Cairo University, 12211 Giza, Egypt.

Abstract

A HIGHLY contagious skin condition called sarcoptic mange spreads through skin-to-skin contact. This study aims to evaluate the health status of rabbits with *Sarcoptes scabiei* regarding lesion score concerning treatment trials using Neem extract evaluation of physiological parameters. From August 2022 to August 2023, 200 domestic rabbits were examined carefully for the presence of mange in their bodies, lesion scores were recorded, as was the collection of sera for biochemical analysis with infested skin and spleen from the infested animals. The infested rabbits were classified into eight groups (6 groups with lesion scores from 0-5): negative control rabbits with no lesion, normal control rabbits, and positive control rabbits treated with Ivermectin alone. Every group has ten rabbits. Serum nitric oxide (NOx) and major histocompatibility class I (MHC-I) were evaluated. The affected rabbits suffered from malnourishment and emaciation. There were also indications of scratching, itching, fur loss, hyperemia, and skin thickening with crust formation. Serum nitric oxide was evaluated according to lesion score, a score of 0 was negative and healthy, and then the nitric oxide (NOx) serum levels were elevated according to the increase in the severity of the diseases with lesion score, this NOx was lower after treatment. Measurable quantities of MHC-I mRNA were examined in each group's lesion score in the skin or spleen. The spleen expression profile was higher in all groups than in the skin. With the increase in the score, the transcript levels increase. This MHC-I level was lower after treatment. Conclusion: The infestation with scabies in rabbits elevated the stress factor, which was then downregulated using one of the eco-friendly agents against these parasites, which had no resistance in rabbits.

Keywords: Sarcoptic mange, Nitric oxide (NOx), Major histocompatibility class I (MHC-I), Neem extract, Essential oil treatment.

Introduction

The parasite that causes scabies is *Sarcoptes scabiei* (*S. scabiei*) [1], which is highly contagious. As they feed on serum and epithelial cells through the skin's pores, these mites can cause severe skin sores. This parasitic skin disease is widespread worldwide and affects many hosts, including humans, domestic animals, and wildlife [2,3].

The ectoparasite *S. scabiei* var. *cuniculi* deserves special attention because it is one of the most common ones that infest rabbits and causes sarcoptic damage. Rabbits infested with *S. scabiei* var. *cuniculi* develop a relative resistance to subsequent

infestation. Even if kept apart from all companion animals, such as dogs, cats, horses, ruminants, pigs, and rabbits in veterinary care, its infection in rabbits causes significant production losses (reduced output and weight loss), painful skin scratching, and sores, and could even result in death in situations when the infestation is getting worse. These mites create tunnels where females can lay eggs or burrow mites [3].

A highly contagious skin condition called sarcoptic mange spreads through skin-to-skin contact, contact with infected fomites, or visiting areas where severely affected hosts are present [4]. They are located in the epidermis' top layers. *S.*

*Corresponding author: Marwa M.A. Attia, E-mail: marwaattia.vetpara@yahoo.com Tel.: 01006765862

(Received 21 December 2023, accepted 14 July 2024)

DOI: 10.21608/EJVS.2024.257222.1739

©National Information and Documentation Center (NIDOC)

scabiei completes its entire life cycle on the host, which takes around three weeks. The larvae move to the skin's surface after hatching to complete their life cycle by maturing into nymphs and eventually adults [5].

The only species of *Sarcoptes* recognized is *S. scabiei*, which tunnels into the skin to complete its life cycle from the egg to the adult form. The female injects eggs into the skin's stratum corneum tunnels, resulting in skin rashes, inflammation, and hypersensitivity [6]. Mites consume lymph and epithelial slough. It is a contagious, yearly, itchy ectoparasitic infestation affecting several experimental animals, including rabbits [3]. The epidermis of the skin is infested with *S. scabiei* mites. Within a few hours of infestation, the female parasite lays eggs after mating. Female then continues to lay two to three eggs per day. The eggs hatch and develop into adult mites in around ten days [7].

Isoxazolines are a potent new class of effective ectoparasiticides that may improve essential parasite management and decrease the risk of disease transmission. For the treatment of sarcoptic mange in several animal species, chemical acaricide medications such as organophosphates, macrocyclic lactones, formamidines, pyrethroids, and isoxazolines are approved for use in veterinary medicine but those chemical pesticides the animals formed a resistance and precipitate in the muscles of the animals forming drugs residues which form a hazards to human being, [5]. The primary constituents of essential oils typically dictate their biological properties. Based on the EOs analysed, a number of significant components were discovered in the current investigation. Specifically, the primary constituents of lemon myrtle and litsea—two of the most effective essential oils which tested were geraniol and nerol. Essential oils (E.O.s) are simple to use, biodegradable, have low ecotoxicity and have very little environmental residual activity because of their high volatility, [9]. Some E.O.s, such as cinnamon and tulsi, have shallow MIC values, while others, such as lemongrass, along with some terpenes (geraniol, eugenol, and citral), also exhibit ovicidal effects. Some E.O.s, such as ahiberol, are effective through contact and in fumigant form, [3,9-12].

This study aims to assess the treatment trials of sarcoptic mange rabbits with plant extracts as neem with the assessment of the treatment trials using physiological parameters.

Experimental

Examined animals

From August 2022 to August 2023, 200 domestic rabbits were examined carefully for the presence of mange in their bodies, lesion scores were recorded, as well as the collection of sera for biochemical

analysis, with infested skin and spleen from the infested animals. The clinical skin lesions were present around the head, ears, neck, trunk, feet, and genitalia, which determine the lesion score. Eighty domestic-infested rabbits were chosen from a particular farm of the Faculty of Agriculture, Cairo University, Seddiek *et al.* [13]. This study was approved by the Animal Care and Use Committee of Cairo University (Approval number: Vet CU 03162023698) and performed by the "Guidelines for Experimental Animals of the Faculty of Veterinary Medicine, Cairo University, Egypt.

Skin scraping test

The usual protocol was used to collect the skin scrapings from diseased rabbits aseptically. After moisturizing the wounded skin with mineral oil, 2.5 cm² of skin was scraped away with a clean, sharp blade till gushing blood was observed. Each skin scraping was individually collected in a plastic bag labeled with the tested rabbits' details to validate the diagnosis [13].

Evaluation of lesion score

The skin lesion scores on the external ear margins, head, nose, and toes were indexed to differentiate the severity (mild/moderate/severe) of clinical infestation: A score 0 indicates no skin lesions.

Score 1: Skin reddening and dryness/head lesion

Score 2: Depilation and wet lesions with significant exudation with head lesion.

Score 3: Severe hair loss, crust increase apparent, approximately half of the external ear edge covered with crusts, head lesions.

Score 4: Crust thickens and spreads to the toes, the external ear edge's crust coverage thickens and increases, head lesions.

Score 5: Thick, wrinkled skin with hyperkeratinization on the toes, almost the entire external ear edge is covered with crusts with severe head lesions.

Plant extract materials

Azadirachta indica (*A. indica*) and Dimethyl sulfoxide (DMSO) were purchased from Sigma-Aldrich®. A stock solution of 20 mM Neem in DMSO was made for the mortality assay and then diluted before being employed in the study. According to Seddiek *et al.* [13], different dilutions ranging from (25% and 50%) were made in distilled water (D.W.), which is the best dilution according to previous reports. Ivermectin solution (0.2% Ivomec®) was used as positive control study.

Treatment trials

The crust was made visible by softly clipping the hair in the afflicted area around the toes of the 80

rabbits. Each of the cleaned toes was treated with a cotton swab soaked in 2.5 ml of the appropriate extract, embrocated with the extract, and the diseased areas of the toes were painted over with the extract as part of the therapy process. In order to cover the affected area with a thin film during these treatments, enough extract was administered [13,14]. Ivermectin (by injection, positive controls) The treatment was repeated another time in 1 week.

On days 14 days of treatment, the evaluation for nitric oxide and gene expression analysis were done.

Biochemical test analysis

Infested and un-infested control and treatment group score rabbits were divided into ten rabbits per group according to lesion score and blood sampled from ear vein for five milliliters each and gently ejected into tubes without anticoagulant. The samples were collected in sterile, anticoagulant-free containers. The sera samples were collected and stored at -20 °C.

Indirect quantification of serum nitric oxide (NO_x) was used to analyze the NO radical dot levels in the serum of infested rabbits[15],described this method. As a result, 50 µL of the sample was used to test the NO_x using the modified Griess method and the Cobas Mira automated analyzer. Results for NO_x were given in units of µmol/L [16].

Evaluation of transcript levels of different genes

Skin from all groups with different scores was also subjected to RNA extraction, and non-infested healthy rabbits were also assessed as negative control.

The manufacturer's instructions used the total RNA kit (Ambion, Applied Biosystems) to isolate mRNA from 100 mg of the sampled parts (skin). The quality and amount of the RNA were assessed using the Nano-Drop from Thermo Scientific. Notably, 500 ng of RNA was generated using DNase I amplification grade (Invitrogen) per the manufacturer's instructions. The High-Capacity cDNA Archive Kit performed the reverse transcription on the treated RNA (Applied Biosystems).

Major histocompatibility class I (MHC-I) specific PCR primer sets for rabbits were designed based on sequences (NM_001190434.1) deposited in the GenBank[18]. For sample normalization and as a reference gene, β-actin was used. These genes were expressed on a unique pool of cDNA produced from rabbits that had not yet been exposed to parasites. Initial denaturation of the PCR took place for 10 min at 95 °C, followed by 40 cycles of denaturation

lasting 30 s at 95 °C, 30 s at 60 °C, 45 s at 72 °C, and 10 min at 72 °C.

Statistical evaluation

The impact of lesion score with infestation rate was investigated using the Chi-square test. Statistics were applied to the results of the biochemical analyses using two-way ANOVA.

All of the data were analyzed using SPSS software, as stated. For all studies, $P < 0.05$ was chosen as the significance criterion.

Results

Clinical indicators and a physical assessment

The affected rabbits had poor bodily condition, emaciated and lowered appetites. There were indications of scratching, itching, fur loss, hyperemia, and thicker skin. The infested rabbits were displayed hyperkeratotic crusty, scaly lesions on various body sections, as well as multifocal patches of alopecia. The skin of the legs and face had lesions around the eyes, nose, ears, neck, and face. The affected rabbits suffered from malnourishment and emaciation. There were also indications of scratching, itching, fur loss, hyperemia, and skin thickening with crust formation. The degree of these clinical symptoms differed among the affected rabbits. On the skin of the face, there were crusty, scaly lesions near the nose, eyes, and ears, Fig.1. The rabbits were classified into six scores: negative healthy ones and positive control with chemical treatment.

Morphological analysis

Sarcoptes scabiei (*S. scabiei*, Linnaeus, 1758) was recognized as the name of the itch mite. Legs I and II emerge from the idiosoma anteriorly (Fig. 2). The male mites' legs I, II, and III have two claws that resemble spurs, but their legs 3 and 4 only have one. All of their legs end in lengthy setae.

Biochemical analysis

Serum nitric oxide was evaluated according to the lesion score, Fig.3, score 0 was negative healthy, then the nitric oxide serum levels were elevated with an increase in the severity of the diseases and lesion score. This elevation decreased gradually after treatment.

Measurable quantities of MHC-I mRNA were examined in each group lesion score in the skin and the spleen. The spleen expression profile was higher in all groups than in the skin. With the increase of the score lesion, the transcript levels increase, this elevation decreases gradually after treatment (Fig.4).



Fig. 1. Different rabbits' groups infested with *Sarcoptes scabiei*, A: Score 0, B: Score 1, C: Score 2, D: Score 3, E: Score 4, F: Score: 5.

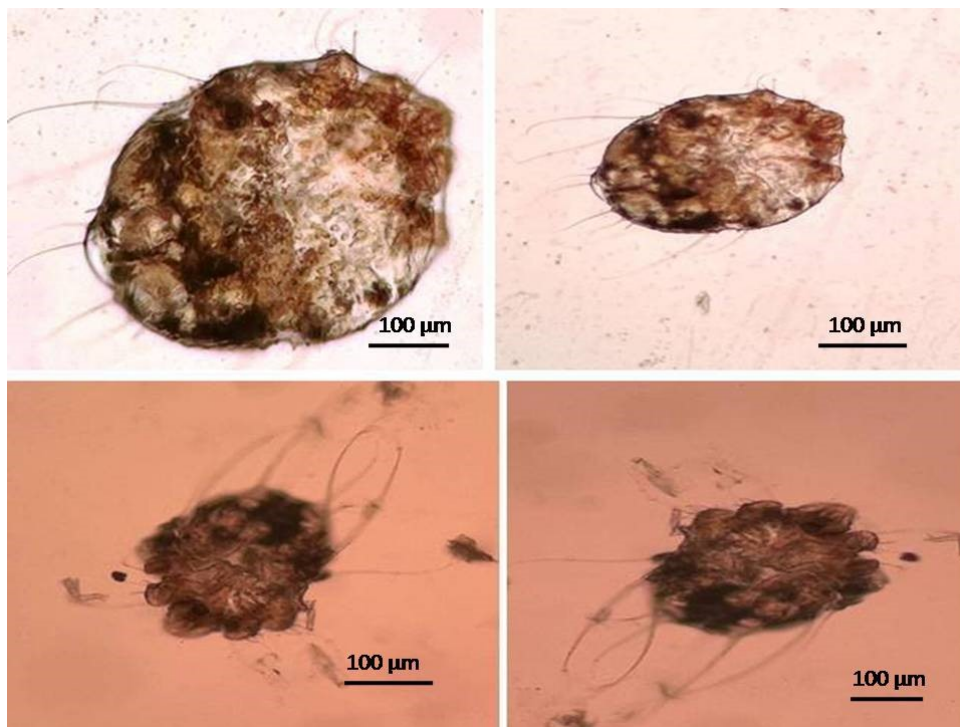


Fig. 2. *S. scabies* infested rabbits with transverse striations, scales, and spines on its dorsal surface.

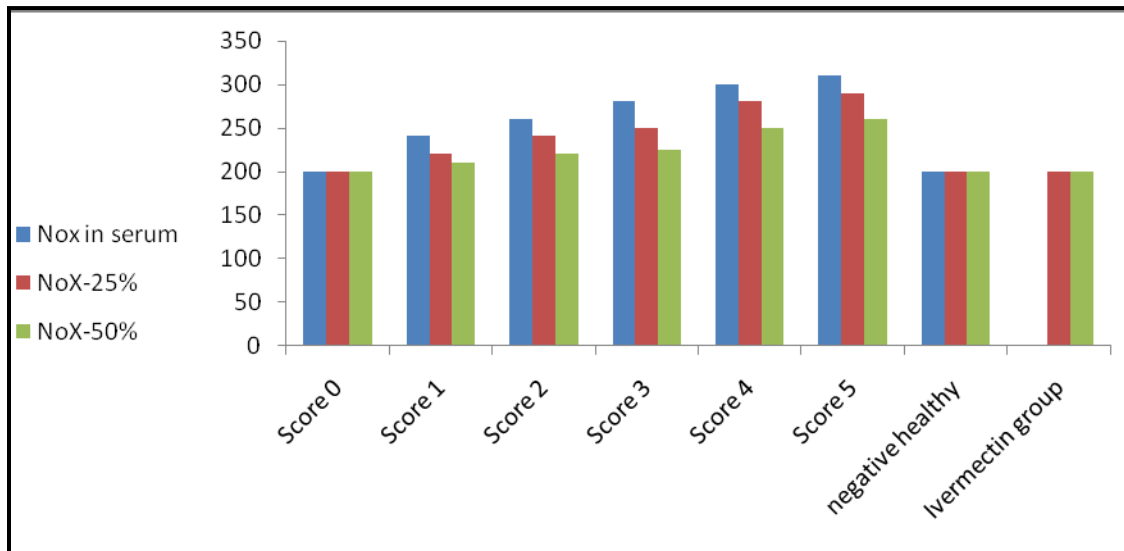


Fig. 3. Nitric oxide (No_x) levels in serum in relation to lesion score and two treatment groups (25%-50%) from score 0 to 5 in contrast to negative control healthy one.

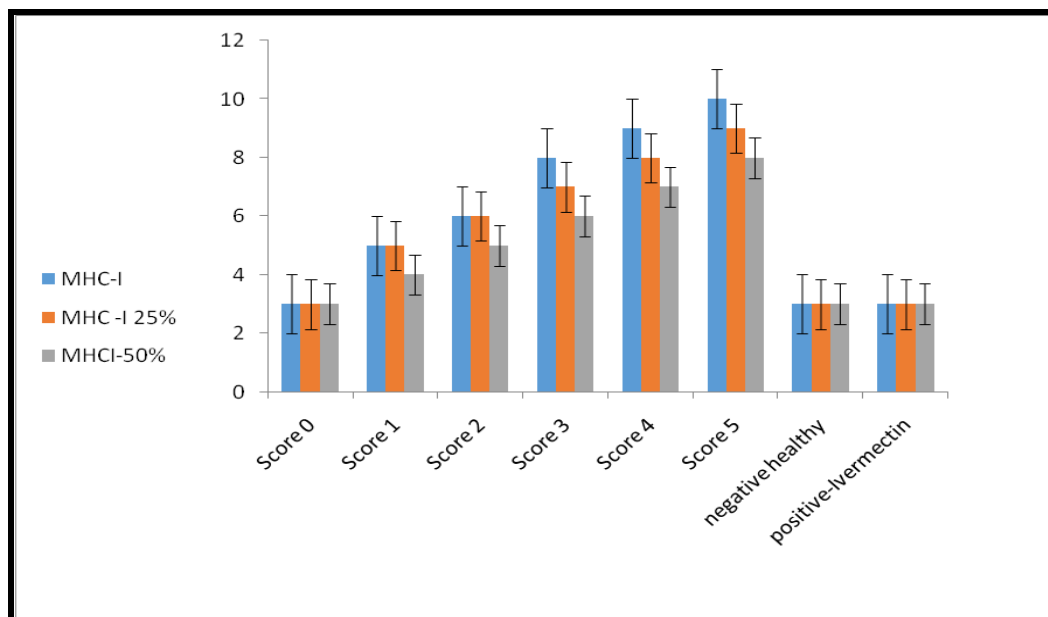


Fig. 4. Major histocompatibility class I in skin and spleen in relation to lesion score and two treatment groups (25 and 50%) from score 0 to 5 in contrast to negative control healthy one.

Discussion

Azadirachta indica, a native to India and used extensively in traditional medicine for a wide range of therapeutic purposes, is the source of neem oil. Although it can also be isolated from fruits, the most often used E.O. comes from kernels. Although the kernel contains more than 300 chemicals, the complete composition has yet to be identified, [17,19,20].

The primary component of neem, azadirachtin, is present in the seed and leaves [21], and has a

concentration of 300–1.300 mg/kg. Neem oil's pesticide properties are thought to be caused by this substance [22]. It has a repulsive impact and has the power to cause growth deregulation, ecdysone level reductions, changes in development and reproduction, and harm to the molting process. Although neem at concentrations ranging from 20% to 60% showed that azadirachtin acts by thinning and weakening the exoskeleton of semi-engorged females of *Rhipicephalus sanguineus*, promoting the absorption of toxins and the rupture of the

integument, it is reported to have no effects on *Sarcoptes* mites [23].

The acaricide effect against *Sarcoptes* has been attributed to four fractions, active on *S. scabiei* var *cuniculi* larvae, [24,25], and octadecanoic acid-tetrahydrofuran-3,4-diyl ester [24], capable of damaging the mites' body walls, interfering with mitochondrial function and the oxidative phosphorylation pathway, and killing the parasites, [18, 26]. Neem kernel aqueous and methanolic extracts applied topically to sheep that were naturally infected over 20 days were found to have a potent acaricide effect, [14].

Commercially, neem is utilized as a pesticide and repellent. The biological substance (MiteStop[®]), based on an extract of neem seeds, significantly reduced the number of bloodsucking mosquitoes, tabanids, ceratopogonids, simuliids, and licking flies attracted. The medication is highly and broadly effective against various insects, ticks, and mites that prey on humans, animals, and birds, [27-28].

Reactive oxygen species (ROS) and free radicals have been linked to significant tissue damage in several clinical diseases [31].

Nitrogen oxides and nitrates are formed when NO radical interacts with oxygen species and biological molecules such as dioxygen, superoxide anion, and oxyhemoglobin [15,16]. The primary stable metabolites of endogenous NO radicals are nitrates and nitrites, which can be quantitatively analyzed [32]. Due to the difficulty in determining NO radical due to its extremely short half-life, measurements of NO radical stable end products, nitrites/nitrates (NOx), are most frequently employed to assess NO radical generation [15].

Reactive oxygen species (ROS) and free radicals have been linked to significant tissue damage in several clinical diseases [16,31].

The quantity of nitrites/nitrates in the serum of Sarcoptic mange animals rose on scores 4 and 5. The research suggests that NO radical may be directly associated with increasing the severity of the disease or parasitemia, the severity of lesions. Several studies conducted in vitro demonstrated the ability of NO radical to radicalize parasites such as *Plasmodium* and *T. cruzi*, [33,34].

Interferon-gamma, tumor necrosis factor-alpha, and interleukin 1 and 6 levels all gradually increased during the acute phase of the infestation, according to a recent study by Paim *et al.*, [36].

Different biological processes are carried out by NO radicals, which can alter infectious diseases. Important neurotransmitter NO radical can be cytotoxic to nerve cells and induce neurological symptoms, as seen in trypanosomiasis cases caused by *T. evansi* and *T. brucei*, Paim *et al.* [36,37]

described the rise in 3-NT in the brains of *T. evansi*-infected rats and behavioral modifications. Our results show that the parasites increase with the nitric oxide levels in the lesion score 5.

In contrast to human and mouse MHC class I genes, which express multiple MHC class I antigens, rabbit MHC class I (RLA) was cloned in 1985 and comprises only one gene locus that can be transcribed and expressed in one RLA haplotype, Zhang *et al.* [38].

The major histocompatibility complex (MHC) genes are among the most variable genes in the vertebrate genomes and serve a critical role in the immune response. It is generally accepted that co-evolution between hosts and parasites maintains the MHC's highly polymorphic nature. The intensity of the infestation in rabbits among different breeds can be intuitively reflected by the clinical condition shown by relative body weight growth and skin lesions. According to Aiello *et al.* [39], *S. scabiei* var. *cuniculi* infestation in rabbits' results in intense scratching, skin lesions, and considerable weight loss.

These two clinical criteria are essential for estimating the intensity of the *S. scabiei* var. *cuniculi* infestation in rabbits. The reference markers for comparing the influence on the immune responses to *S. scabiei* var. *cuniculi* have been considered the respective skin lesions. According to a laboratory infection study by Elder *et al.* [40], Wedekind *et al.* [41], and Westerdahl *et al.* [41], MHC can affect the ability to manage an infection's intensity and clear an infection.

Previous research on songbirds has discovered relationships between specific MHC class I alleles and parasites such as avian malaria infection, Westerdahl *et al.* [41], Sepil *et al.* [43]. The pathogenic effects of these mites have been linked to their burrowing behavior, the mechanical harm the parasites inflict during excavation, the irritant action of their secretions and excretions, allergic reactions to some of their extracellular products, and particularly the release of the cytokine IL-1,[43].

Medicinal plants are rich in antioxidants and medicinal substances, essential oils (EOs) are blends of volatile substances that are often extracted via steam or hydro-distillation from aromatic plants [44-46]. These substances belong to two different biosynthetic groups. Terpenes and terpenoids make up the main group, while aromatic and aliphatic elements make up the other group. All of these constituents have a low molecular weight. Different plant parts, including leaves, flowers, seeds, grasses, and dried flower buds, can be used to extract essential oils, which can be effective on pathogens or various diseases agents [46-48].

Conclusion

E.O.s is one of the upcoming trends as acaricides and for their most potent constituents. This study revealed its potency in treatment regimens as, after the elevation of the oxidative stress and gene expression in the infestation score, they down-regulate again.

Acknowledgment: Many thanks to the staff workers for handling rabbits during this experiment.

Ethical Approval and Consent to Participate: This study was approved and follow the guidelines of the Ethical committee of the Faculty of Veterinary medicine, Cairo University with number Vet CU 03162023698, these experiments were performed in compliance with the ARRIVE guidelines.

Competing interests: All authors declare that they have no conflict of interest.

Funding statement: No funding supporting this work.

Availability statement: All the authors declare that, all the data supporting the results reported in our article were found included in this article only.

Availability of data and material: all data from our work and available in this manuscript.

Consent to Publish: Not Applicable.

Author Contribution

All authors contributed equally in this study. All authors write the manuscript, revised it. All authors read and approved the final manuscript.

References

- Hengge, U. R., Currie, B. J., Jäger, G., Lupi, O. and Schwartz, R. A. Scabies: a ubiquitous neglected skin disease. *The Lancet. Infectious Diseases*, **6**(12), 769 – 779(2006). [https://doi.org/10.1016/S1473-3099\(06\)70654-5](https://doi.org/10.1016/S1473-3099(06)70654-5)
- Arlan, L.G. and Morgan, MS. A review of *Sarcoptes scabiei*: past, present and future. *Parasit. Vectors*, **10**(1), 297(2017). doi: 10.1186/s13071-017-2234-1. PMID: 28633664, PMCID: PMC5477759.
- Nardoni, S. and Mancianti, F. Essential Oils against *Sarcoptes scabiei*. *Molecules* (Basel, Switzerland), **27**(24), 9067 (2022). <https://doi.org/10.3390/molecules27249067>.
- Alasaad, S., Rossi, L., Heukelbach, J., Pérez, J.M., Hamarsheh, O., Otiende, M. and Zhu, X.Q. The neglected navigating web of the incomprehensibly emerging and re-emerging *Sarcoptes* mite. *Infect. Genet. Evol.*, **17**, 253–259(2013).
- Bernigaud, C., Fischer, K. and Chosidow, O. The Management of Scabies in the 21st Century: Past, Advances and Potentials. *Acta Derm. Venereol.*, **100**, 112 (2020).
- Millán, J., Casáis, R., Delibes-Mateos, M., Calvete, C., Rouco, C., Castro, F., Colomar, V., Casas-Díaz, E., Ramírez, E., Moreno, S., Prieto, J. M. and Villafuerte, R. Widespread exposure to *Sarcoptes scabiei* in wild European rabbits (*Oryctolagus cuniculus*) in Spain. *Veterinary Parasitology*, **183** (3-4), 323–329(2012). <https://doi.org/10.1016/j.vetpar.2011.07.046>.
- Abdel-Ghaffar, F., Al-Quraishy, S., Sobhy, H.M. and Semmler, M. Neem seed extract shampoo, Wash away Louse®, an effective plant agent against *Sarcoptes scabiei* mites infesting dogs in Egypt. *Parasitol. Res.*, **104**,145–148(2008).
- Urainab S, Mehreen A. and Zahid S. Essential Oils Have the Potential to Be Effective *Therapeutic Agents in the Future*, **4** (1), 17-23 (2022). doi: 10.52547/pbp.4.1.4.
- Rahmati M, Shokri S, Ahmadi M, Ahmadi M, Marvi Moghadam N, and Seyfi S. Comparison of Pesticide Effect of Copper Oxide Nanoparticles Synthesized by Green Chemistry and Plant Extracts on *Anopheles Stephensi*. *Mosquitoes*, **4** (1), 79-86 (2022). doi: 10.52547/pbp.4.1.11.
- Nong, X., Ren, Y. J., Wang, J. H., Xie, Y., Fang, C. L., Yang, D. Y., Liu, T. F., Zhang, R. H., Chen, L., Gu, X. B., Peng, X. R., Wang, S. X., Lai, S. J., and Yang, G. Y. Clinical efficacy of botanical extracts from *Eupatorium adenophorum* against the *Sarcoptes scabiei* (Sarcoptidae: Sarcoptes) in rabbits. *Veterinary Parasitology*, **195**(1-2), 157–164 (2013). <https://doi.org/10.1016/j.vetpar.2013.02.020>.
- Andriantsoanirina, V., Guillot, J., Ratsimbason, M., Mekhloufi, G., Randriamialinoro, F., Ranarivelo, L., Ariey, F. and Durand, R. In vitro efficacy of essential oils against *Sarcoptes Scabiei*. *Scientific Reports*, **12**, 7176 (2022).
- Shamseldean, M. S. M., Attia, M. M., Korany, R. M. S., Othamn, N. A. and Allam, S. F. M. Insecticidal efficacy of nanomaterials used to control mosquito, *Culex quinquefasciatus* Say, 1823 with special reference to their hepatotoxicity in rats. *Bioscience Reports*, **42** (7), BSR20220630 (2022). <https://doi.org/10.1042/BSR20220630>.
- Seddiek, S.A., Khater, H.F., El-Shorbagy, M.M. and Ali, A.M. The acaricidal efficacy of aqueous neem extract and Ivermectin against *Sarcoptes scabiei* var. *cuniculi* in experimentally infested rabbits. *Parasitology Research*, **112**, 2319–2330 (2013).
- Soulsby, E.J.L. *Helminths, Arthropods and Protozoa of Domesticated Animals*. 7th Edition, Balliere, Tindall and Cassel, London, (1982).
- Tabassam, S.M., Iqbal, Z., Jabbar, A., Sindhu, Z.U. and Chattha, A.I. Efficacy of crude neem seed kernel extracts against natural infestation of *Sarcoptes scabiei* var. *ovis*. *Journal of Ethnopharmacology*, **115**, 284–287 (2008).
- Tatsch E., Bochi, G.V., Pereira, R.S., Kober, H., Oliveira, J.R. and Moresco, R.N. A simple and inexpensive automated technique for measurement of serum nitrite/nitrate. *Clinical Biochemistry*, **44**, 348-350 (2011).

17. Alvares, F. B. V., Meireles, V. S. R. V., da Silva, J. T., Ferreira, L. C., Rodrigues, J. A., Bezerra, R. A. and Vilela, V. L. R. Laboratory diagnosis of mange-causing mites in dogs using a modified centrifugation-flotation technique in sucrose solution. *Experimental and Applied Acarology*, **85**, 41–48 (2021).
18. Tykocinski, M. L., Marche, P. N., Max, E. E. and Kindt, T. J. Rabbit class I MHC genes: cDNA clones define full-length transcripts of an expressed gene and a putative pseudogene. *Journal of Immunology (Baltimore, Md.: 1950)*, **133**(4), 2261–2269 (1984).
19. Chen, Z.Z., Deng, Y.X., Yin, Z.Q., Wei, Q., Li, M., Jia, R.Y., Xu, J., Li, L., Song, X. and Liang, X.X. Studies on the acaricidal mechanism of the active components from neem (*Azadirachta indica*) oil against *Sarcoptes scabiei* var. *cuniculi*. *Veterinary Parasitology*, **204**, 323–329 (2014).
20. Benelli, G., Canale, A., Toniolo, C., Higuchi, A., Murugan, K., Pavela, R. and Nicoletti, M. Neem (*Azadirachta indica*): Towards the ideal insecticide? *Nat. Prod. Res.*, **31**, 369–386 (2017).
21. Gupta, S.C., Prasad, S., Tyagi, A.K., Kunnumakkara, A.B. and Aggarwal, B.B. Neem (*Azadirachta indica*): An indian traditional panacea with modern molecular basis. *Phytomedicine*, **34**, 14–20 (2017).
22. Brahmachari, G. Neem-An omnipotent plant: A retrospection. *Chembiochem European Journal of Chemistry*, **5**, 408–421 (2004).
23. Isman, M.B., Koul, O., Luczynski, A. and Kaminski, J. Insecticidal and antifeedant bioactivities of neem oils and their relationship to azadirachtin content. *Journal of Agriculture and Food Chemistry*, **38**, 1406–1411 (1990).
24. Walton, S.F., Myerscough, M.R. and Currie, B.J. Studies in vitro on the relative efficacy of current acaricides for *Sarcoptes scabiei* var. *hominis*. *Transactions of the Royal Society of Tropical Medicine and Hygiene*, **94**, 92–96 (2000).
25. Du, Y.H., Jia, R.Y., Yin, Z.Q., Pu, Z.H., Chen, J., Yang, F., Zhang, Y.Q. and Lu, Y. Acaricidal activity of extracts of neem (*Azadirachta indica*) oil against the larvae of the rabbit mite *Sarcoptes scabiei* var. *cuniculi* in vitro. *Veterinary Parasitology*, **157**, 144–148 (2008).
26. Deng, Y., Shi, D., Yin, Z., Guo, J., Jia, R., Xu, J., Song, X., Lv, C., Fan, Q. and Liang, X. Acaricidal activity of petroleum ether extract of neem (*Azadirachta indica*) oil and its four fractions separated by column chromatography against *Sarcoptes scabiei* var. *cuniculi* larvae in vitro. *Experimental Parasitology*, **130**, 475–477 (2012).
27. Song, X., Chen, Z., Jia, R., Cao, M., Zou, Y., Li, L., Liang, X., Yin, L., He, C. and Yue, G. Transcriptomics and proteomic studies reveal acaricidal mechanism of octadecanoic acid-3, 4-tetrahydrofuran diester against *Sarcoptes scabiei* var. *cuniculi*. *Scientific Reports*, **7**, 45479 (2017).
28. Abdel-Ghaffar, F., Semmler, M., Al-Rasheid, K.A.S. and Mehlhorn, H. In vitro efficacy of ByeMite[®] and Mite-Stop[®] on developmental stages of the red chicken mite *Dermanyssus gallinae*. *Parasitology Research*, **105**, 469–471 (2009).
29. Abdel-Ghaffar, F., Semmler, M., Al-Rasheid, K., Klimpe, I. S. and Mehlhorn, H. Comparative in-vitro test on the efficacy and safety of 13 anti-head-lice products. *Parasitol. Res.*, **106**, 423–249(2010).
30. Al-Quraishy, S., Abdel-Ghaffar, F., Al-Rasheid, K.A., Mehlhorn, J. and Mehlhorn, H. Observations on effects of a neem seed extract (MiteStop[®]) on biting lice (mallophages) and bloodsucking insects parasitizing horses. *Parasitology Research*, **110** (1), 335–339 (2012a).
31. Al-Quraishy, S., Abdel-Ghaffar, F., Al-Rasheid, K.A., Mehlhorn, J. and Mehlhorn, H. Effects of a neem seed extract (MiteStop[®]) on mallophages (featherlings) of chicken: in vivo and in vitro studies. *Parasitol. Res.*, **110**(2), 617–622(2012b).
32. Nohl, H., Esterbauer, H. and Evans, C.R. Free radicals in the environment, medicine and toxicology: critical aspects and current highlights. *Free Radical Biology & Medicine*, **20**, 765-766 (1996).
33. Romitelli, F., Santini, A.S., Chierici, E., Pitocco, D., Tavazzi, B. and Amorini, A.M. Comparison of nitrate/nitrite concentration in human plasma and serum samples measured by the enzymatic batch Griess assay, ion-pairing HPLC and ion-trap GC-MS: the importance of a correct removal of a correct removal of proteins in the Griess assay. *Journal of Chromatography B: Analytical Technologies in the Biomedical and Life Sciences*, **851**, 257-267(2007).
34. Boutlis, C.S., Weinberg, J.B., Baker, J., Bockarie, M.J., Mgone, C.S., Cheng, Q. and Anstey, N.M. Nitric oxide production and nitric oxide synthase activity in malaria-exposed papua new guinean children and adults show longitudinal stability and no association with parasitemia. *Infection and Immunity*, **72**, 6932-6938(2004).
35. Vespa, G.N.R., Cunha, F.Q. and Silva, J.S. Nitric oxide is involved in control of *Trypanosoma cruzi*-induced parasitemia and directly kills the parasite in vitro. *Infection and Immunity*, **62**, 5177-5182 (1994).
36. Paim, F.C., Duarte, M., Wolkmer, P., Da Silva, A.S., Costa, M.M., da Silva, C.B., Monteiro, S.G. and Lopes, S.T. Cytokines in rats experimentally infected with *Trypanosoma evansi*. *Experimental Parasitology*, **128**, 365-370 (2011).
37. Paim, F.C., Da Silva, A.S., Wolkmer, P., Costa, M.M., da Silva, C.B., Monteiro, S.G. and Lopes, S.T. *Trypanosoma evansi*: concentration of 3-nitrotyrosine in the brain of infected rats. *Experimental Parasitology*, **129**, 27-30 (2011).
38. Zhang, Q., Liu, K., Yue, C., Zhang, D., Lu, D., Xiao, W. and Liu, W. J. Strict assembly restriction of peptides from rabbit hemorrhagic disease virus presented by rabbit major histocompatibility complex class I molecule RLA-A1. *Journal of Virology*, **94**(17), 10-1128 (2020).
39. Aiello, S.E., Mays, A. and Amstutz, H.E. Rabbits. In: Aiello, S.E., Moses, M.A., editors. *The Merck Veterinary Manual*. New Jersey: Merck Inc, 1386–1396 (1988).

40. Elder, B.L., Arlian, L.G. and Morgan, M.S. *Sarcoptes scabiei* (Acari: Sarcoptidae) mite extract modulates expression of cytokines and adhesion molecules by human dermal microvascular endothelial cells. *Journal of Medical Entomology*, **43** (5), 910-915 (2006). doi: 10.1603/0022-2585(2006)43[910:ssasme]2.0.co.2. PMID: 17017228, PMCID: PMC1781343.
41. Wedekind, C., Walker, M. and Little, T.J. The course of malaria in mice: Major histocompatibility complex (MHC) effects, but no general MHC heterozygote advantage in single-strain infections. *Genetics*, **170**, 1427–1430(2005) 10.1534/genetics.105.040683.
42. Westerdahl, H., Stjernman, M., Råberg, L., Lannefors, M. and Nilsson, J.Å. MHC-I Affects Infection Intensity but Not Infection Status with a Frequent Avian Malaria Parasite in Blue Tits. *PLoS ONE* **8**(8), e72647. (2013). <https://doi.org/10.1371/journal.pone.0072647>.
43. Sepil, I., Lachish, S., Hinks, A.E. and Sheldon, B.C. Mhc supertypes confer both qualitative and quantitative resistance to avian malaria infections in a wild bird population. *Proceedings of the Royal Society of London. Series B, Biological Sciences*, **278**, 1025–1033 (2013).
44. Abbasi, N., Akhavan, M. M., Rahbar- Roshandel, N. and Shafiei, M. The effects of low and high concentrations of luteolin on cultured human endothelial cells under normal and glucotoxic conditions: involvement of integrin-linked kinase and cyclooxygenase-2. *Phytotherapy Research*, **28**(9), 1301-1307 (2014).
45. Razmjoue, D., Pirhadi, M., Soltanbeigi, A., Lysiuk, R., Asadzadeh, R. Investigating the effect of total antioxidant capacity of medicinal plants *Salsola rigida* and *Triticum aestivum*. *Plant Biotechnology Persa*, **5** (2),1-6(2023). URL: <http://pbp.medilam.ac.ir/article-1-204-en.html>.
46. Shi, Z., Mahdavian, Y., Mahdavian, Y., Mahdigholizad, S., Irani, P., Karimian, M. and Zangeneh, M. M. Cu immobilized on chitosan-modified iron oxide magnetic nanoparticles: Preparation, characterization and investigation of its anti-lung cancer effects. *Arabian Journal of Chemistry*, **14**(8), 103224. (2021).
47. Akram, M., Rashid, A., Khalil, M. T., Anwar, H., Siddique, A., Shahid, N. and Sołowski, G. Herbal Treatment of Hypertension: A Literature Review. *Journal of Biochemicals and Phytomedicine*, **2**(1), 20-24 (2023).
48. Aidy, A., Karimi, E., Ghaneialvar, H., Mohammadpour, S. and Abbasi, N. Protective effect of Nectaroscordumtripedale extract and its bioactive component tetramethylpyrazine against acetaminophen-induced hepatotoxicity in rats. *Advances in Traditional Medicine*, **20**, 471-477 (2020).

تقييم معاملة الزيوت العطرية لمستخلص النيم مقابل الإيفرمكتين ضد داء الجرب في قطعان الأرناب

اسامة صقر¹، حسناء ثابت² ومروة محمد عطية³

¹ قسم الإنتاج الحيواني - كلية الزراعة - جامعة القاهرة - 12613 - الجيزة - مصر.

² قسم علم الحيوان والحشرات - كلية العلوم - جامعة أسيوط - 71526 - أسيوط - مصر.

³ قسم الطفيليات - كلية الطب البيطري - جامعة القاهرة - 12211 الجيزة - مصر

المستخلص

تنتشر حالة جلدية شديدة العدوى تسمى الجرب القارمي من خلال ملامسة الجلد للجلد. تهدف هذه الدراسة إلى تقييم الحالة الصحية للأرناب المصابة بالقارمة الجربية فيما يتعلق بدرجة الإصابة فيما يتعلق بتجارب العلاج باستخدام مستخلص النيم وتقييم المعلمات الفسيولوجية. وفي الفترة من أغسطس 2022 إلى أغسطس 2023، تم فحص 200 أرناب منزلي بعناية للتأكد من وجود الجرب في أجسامهم؛ تم تسجيل درجات الآفة، فضلاً عن جمع الأمصال للتحليل الكيميائي الحيوي مع الجلد المصاب والطحال من الحيوانات المصابة. تم تصنيف الأرناب المصابة إلى ثماني مجموعات (6 مجموعات بدرجات إصابة من 0-5) وأرناب سيطرة سلبية بدون آفة وأرناب سيطرة طبيعية وإيجابية تعامل بالإيفرمكتين وحده. تحتوي كل مجموعة على عشرة أرناب. تم تقييم أكسيد النيتريك في الدم (NOx) وفئة التوافق النسيجي الرئيسية الأولى (MHC-I). وعانت الأرناب المصابة من سوء التغذية والهزال. كانت هناك أيضاً مؤشرات على الخدش والحكة وفقدان الفراء واحتقان الدم وسماكة الجلد مع تكوين القشرة. تم تقييم أكسيد النيتريك في الدم وفقاً لدرجة الآفة؛ كانت النتيجة (0 سلبية صحية، ثم ارتفعت مستويات مصلى أكسيد النيتريك (NOx) وفقاً للزيادة في شدة الأمراض مع درجة الآفة؛ وكان هذا أكسيد النيتروجين أقل بعد العلاج. تم فحص كميات قابلة للقياس من MHC-I mRNA في كل درجة آفة جماعية في الجلد أو الطحال. كان مظهر تعبير الطحال أعلى في جميع المجموعات منه في الجلد. مع زيادة آفة النتيجة، تزيد مستويات النقص. كان MHC-I أقل بعد العلاج. الاستنتاج: إن الإصابة بالجرب في الأرناب أدت إلى رفع عامل الإجهاد الذي يتم بعد ذلك تنظيمه باستخدام أحد العوامل الصديقة للبيئة ضد هذه الطفيليات التي لم تكن لها مقاومة في الأرناب.

الكلمات الدالة: الجرب القارمي، أكسيد النيتريك (أكاسيد النيتروجين)، فئة التوافق النسيجي الكبرى الأولى (MHC-I)، مستخلص النيم، العلاج بالزيوت الأساسية.