



Comparison Between Omental and Hypericum Perforatum Extracts on Healing of Full Thickness Excisional Skin Wounds in Rabbits

Mohammed S. M. Alnajjar*

Department of Medicine and Surgery, College of Veterinary Medicine, University of Duhok, Iraq.

Abstract

INVESTIGATING clinical and histopathological effects of the topical application of Hypericum and omental extracts on healing in skin wound of the rabbits. Fifteen rabbits were divided into 3 groups (4, 7, and 14-day intervals). In each animal, three circular excisions about 2cm were created, Control defect (CD), Hypericum defect (HD), and Omental defect (OD). Defects were observed clinically for rates of contraction. Biopsies were taken for histopathological examinations; sections were stained with H&E and Mason's trichrome stains. Clinical comparison at 4 days interval showed no significant differences among three groups. At 7 days interval showed significant decrease in size of HD comparing to CD at p -value (0.0132), while there were no significant differences between HD and OD between neither CD nor OD. At 14 days interval, the difference between HD and CD was highly significant (p value 0.0024), between HD and OD was significant (p value 0.0290), while between OD and CD was not significant (p value 0.3717). Histopathological examinations showed increased, number of fibroblasts and collagen, and angiogenesis rate, at 7-day interval and more re-epithelialization at 14-day interval in HD and OD comparing to the CD. It was concluded from results that there were positive effects of Hypericum and Omental extracts on healing process through increasing.

Keywords: Extract, Healing process, Hypericum, Omentum, Rabbits, Skin excisions.

Introduction

Wound is a breaking or losing of cellular and anatomical continuity of the living tissues, and the healing process is a dynamic biological process that is initiated by trauma and often terminated by scar tissue formation. Thus, healing is an essential survival mechanism that try to maintain normal skin anatomical structure and functions like prevention of bacterial invasion, preserving of body fluids and thermoregulation [1,2]. The cutaneous wound healing a complex dynamic process in animals including rabbits, progresses in three overlapping phases: inflammatory phase, proliferative phase, and remodelling phase [3, 4]. According to Grada et al. [5], there are four overlapping phases: coagulation, inflammation, proliferation, and remodelling.

Plants have historically played an important role in the recovery of animal and human health. Hypericum perforatum L. (St. John's wort), a member of the Hypericaceae family, is used as a herbal medicine plant all over the world [6,7].

Because of broad diversity of ingredients (e.g. Hyperforin, Flavonoids and Hypericin), which possess many pharmaceutical effects, the *H. perforatum* has been used both topically and orally to treat many conditions including skin wounds [7,8]. Literatures showed that it increased deposition of collagen and shortened the duration of inflammatory phase [9,10], also it has antibacterial activity [11].

The omentum is a large mesh-like adipose tissue in the abdominal cavity that contains secondary lymphoid organs called milky spots [12]. Fernandes et al. [13] reported that the free omental graft has a positive effect on the healing process of cutaneous wounds that induced experimentally in rabbits. Litbarg et al. [14] propose that an omentum is rich in growth factors that accelerate the process of healing and regeneration of injured tissue. The omentum contains many water-soluble endothelial growth factors like (Vascular endothelial growth factor) VEGF and (Basic fibroblast growth factor) bFGF

*Corresponding authors: Mohammed S. M. Alnajjar, E-mail: bamarny83@uod.ac Tel.: +9647504592159

(Received 23/03/2024, accepted 08/05/2024)

DOI: 10.21608/EJVS.2024.278769.1958

©2025 National Information and Documentation Center (NIDOC)

that induce angiogenesis. The extraordinary ability of the omentum for vascularization of wounded tissue appears to be attributed to the high concentration of VEGF and bFGF, which are about 10 – 100 fold higher in concentrations than other adult organs [15].

The aim of this study was to investigate the clinical and histopathological effects of the topical

Material and Methods

Extracts

Omental extract (OE) preparation

Omenta were collected from local slaughterhouses (from sheep) kept in ice packs until processing. Omentum was cut in to small individual pieces, and about 250 g of omentum were used to prepare extract. Which then put down in a blender containing 400 ml milliliter of phosphate buffered saline (PBS) to form a cream like mixture which then centrifuge to separate fractions into 3 layers that were visible in the bottles: a pellet of mixed composition; a turbid homogenate containing substantially all the proteinaceous material, and a floating, cream colored, lipid cake.

The pellet and the turbid homogenate fractions were discarded completely. The lipid fraction isolated as a floating lipid cake (which contain an active angiogenic factor in substantial quantity). The separated quantities of lipid cake were combined with an organic solvent comprising chloroform and methanol (2:1, v/v) (chloroform = 150 ml, methanol = 75 ml) [16].

The lipid/organic solvent homogenate was then centrifuged at 200 times gravity in a centrifuge at room temperature for 10 minutes. Separate the mixture into clear, golden colored, supernatant and a particulate matter precipitant. The supernatant was placed in the water bath at 37° C for one day to completely remove the chloroform/methanol solvent. Finally the extract was used on the animals.

Hypericum (HE) extract preparation

Aerial parts (Leaves and stems) of Hypericum were dried under shadow and then grounded. 20 gm of the finely grounded plant was extracted in 200 ml of 70% ethanol by using Soxhlet apparatus for about 6 to 7 hours. Then the extract was filtered by filter paper. The filtrate was concentrated by using rotary evaporator under reduced pressure. The crude extract was left overnight in dark place and then kept in dark bottle in refrigerator [17, 18]. The petroleum jelly base was sterilized by dry heat (160C, 90 minutes). Mixing 20% oily extract and 80% petroleum jelly and filling in presterilized tubes were performed in aseptic condition until used.

Animals, procedure and sampling

Fifteen adult, apparently healthy crossed breed rabbits, aged 6-8 months old of both sex (male 6 and

application of H. perforatum and omental extractions on healing in skin wound of the rabbits. Furthermore, to investigate the possibility of these topical agents to be used for open wound management to treat complicated and problematic wounds.

female 9) have been used in this research. The animals were divided into three groups (4-, 7-, and 14-day intervals). In each rabbit of all groups, three defects were created: Control defects (CD), Hypericum defects (HD), and Omental defects (OD). Each group containing 5 rabbits (2) male and (3) female.

Atropine sulfate 0.05 mg/kg b.w have been given subcutaneously as premedication followed by (after 10 minutes) a mixture of ketamine 40mg/kg and Xylazine 4mg/kg intramuscularly [19].

Clipping and shaving of three sites for making skin excision, the right and left gluteal regions and shoulder region, after surgically prepared a 2 cm, full thickness, circular skin excisions were made in the mentioned sites.

The extracts were applied to the created wounds as following: The right gluteal defect was topically applied with Hypericum extract, left gluteal defect with Omental extract, and the shoulder defect were left blank as control. Penicillin streptomycin was injected three days post operatively as prophylactic antibiotic (Interchemie, The Netherlands) at dose rate 40 mg/kg penicillin + 50 mg/kg streptomycin s.c [20].

The size of defects were observed over the period of study and compared to the size at 4, 7, and 14 days intervals by using a ruler with millimeter grading to measure the surface area of defect or surface perimeter area (SPA), and the rates of wound healing (contraction of wound surface) were calculated as following (size of defect at 1st day – size of defect at 4, 7, or 14 day/ size of defect at 1st day) × 100 [21].

Statistical analysis for comparing among the groups, ANOVA pairwise comparison was used, followed by Tukey's multiple comparison test to determine differences at the level of significance was set to 0.05. The statistical software GraphPad Prism version 9 for Windows (Boston, USA) have been used.

Biopsies (at created defects and surrounding skin) were collected from group after 14, 7, and 4 days respectively preserved in 10% formalin until histopathological examination. The tissue sections were stained with (H&E) and Mason's trichrome stain. After sample collection, rabbits were kept alive in which skin wound sutured and recovered from anaesthesia.

Results

Clinical observation

All animals recovered well from the anesthesia and surgical procedures and no deaths were recorded. No significant differences seen in rabbits in all three groups regarding to the activities like appetite, urination, defecation, and alertness. The physiological parameters (temperature, respiratory rate, and heart rate) were within normal ranges.

Created wound were observed over all period of the experiment. The hemorrhage, and exudate were not observed after 1day, redness (erythema) of surrounding skin (Figs.1 &2). The swelling gradually diminished, until completely disappeared on day 5.

The size of created defects were observed all over the period of study and the amount of contraction

Histopathological examinations:

Histopathological examinations, in the current study, depended on the following criteria: infiltration of inflammatory cells (polymorphonuclear and mononuclear cells), fibroblasts proliferation and

Profound infiltration of inflammatory cells mostly neutrophils at 4-day interval in all defects which was more extensive in OD than in CD and HD. At 7 interval, scanty in infiltration of inflammatory cells which was more observed in CD than in OD and HD. Finally at 14-day interval, infiltration of inflammatory was not observed (Absent) except in some samples in which little infiltration was noted.

It was noted that the fibroblast proliferation and migration was scanty in CD and HD defects, and it was moderate in OD defects at interval 4 days. At the 7 days interval fibroblast number profoundly increased in all defects but more obvious in HD. At the 14 days interval, fibroblast numbers were moderate in all groups with increased of amount of

Discussion

The main aim of the treatment of wounds is rapid wound closure to restore its function as a physical barrier to prevent infections and maintaining internal homeostasis (limiting fluid loss and thermal regulation). This study was designed to determine the effect of omental extract or hypericum extract on skin wounds comparing with wounds without any topical agents, and also to determine which extract will accelerate healing process more.

Acute wounds in rabbits, such as those created by surgery or trauma heals in a relatively predictable timeframe about 20 days [1] and about 36 ± 2 in case of burns [22].

The clinical observation of swelling, and erythema of skin surrounding the defect maybe it

(healing rate) was measured and analyzed statistically, so that it can be easily compared with each other. The results were showed in (Table 1) and (Figs. 3, 4, 5). There were no significant differences among groups at interval 4 days at (< 0.05). At the 7 days interval there was significant decrease in size of defects treated with Hypericum (HD) comparing to control defect (CD) p value (0.0132), while there were no significant differences between HD and OD neither between CD and OD. At the 14 days interval, the difference between HD and CD was highly significant (p value 0.0024), between HD and OD was significant (p value 0.0290), while between OD and CD was not significant (p value 0.3717).

collagen fiber deposition, angiogenesis and formation of new capillaries, and reepithelization. These criteria were compared among control defects (CD), Hypericum (HD) defects, and Omental (OD) defects, in three intervals (4, 7, and 14 days) see figures (6, 7, and 8).

collagen fibers which was more obvious in OD and HD than in CD.

Angiogenesis was not started yet, in all defects at 4 day interval, but at 7 days interval there was mild angiogenesis in CD, moderate in HD, and more profound in OD. At 14 days interval, the number of blood vessels were mild in all defects, but they were more organized in granulation tissue. A microvascular network throughout the granulation tissue formed.

Incomplete epithelialization in CD at 14-day interval, while in HD and OD epithelialization was covered most of the surface of defect.

At interval 14 days, hyperkeratosis was noted in HD, less pronounced keratinization in OD comparing to HD, and less in CD.

was due to hyperemia and congestion that occurs as a result of healing process after trauma [23].

The surface perimeter area (SPA) changes which were most obvious at interval 14 days. It was noticed that the HD has a higher rate of reduction of SPA. That reduction may be due to the promotion of fibroblast collagen production and myofibroblasts proliferation, which resulted into higher rate of wound repair by closing the damaged area [24]. Decreasing in SPA in OD is due to the fact that it is rich in growth factors that accelerate the healing and regeneration of injured tissues [14].

Histopathological assessment of biopsies that taken at different intervals of wound healing have been recognized as histopathological hallmark of wound healing. Results of the current study

demonstrated that there were differences between HD and OD comparing to the CD, and also between HD and OD when compared to each other's.

Profound inflammatory cells infiltration in all defects (OD, CD, and HD) at 4 day interval, is a normal biological event in the healing process [4]. The least infiltration of inflammatory cells at 7 day interval was observed in HD. These findings were due to the fact that Hypericum contain Hypericin, which inhibited the pro-inflammatory enzyme janus kinase 1 (JAK1), and Hyperforin which inhibit the activity of cyclooxygenases (COX) 1 and 2 and prostaglandin synthase PGE2, which explained the anti-inflammatory properties of Hypericum [11]. Little inflammatory infiltration that noted in some samples at 14 day interval was probably due to self-mutilation.

Collagen fibers are fundamental element of the extracellular matrix and plays an important role in the healing of cutaneous injuries. The scanty numbers of fibroblasts in defects at interval 4 days, and their profound number at the 7 days interval were probably due to starting of fibroblasts to proliferate and migrate into the wounded areas after 3 days and reach the peak on the seventh day [4].

fibroblast number profoundly increased in all defects but more obvious in HD. At the 14 days interval, fibroblast numbers were notably decreased in all groups with increased of amount of collagen fibers which was more obvious in OD and HD than in CD.

Results of angiogenesis and formation of blood vessels in the current study which showed profound capillary buds in OD comparing to HD and CD. The mechanism of omentum-induced angiogenesis is due

to several growth factors mainly vascular endothelial growth factor (VEGF) and Fibroblast growth factor (FGF) [25]. Formation of new capillaries and blood vessels plays a key role in wound healing process and preventing infection through increasing host defence mechanisms in wounded area.

Conclusion

Based on the above results, it can be concluded that wound healing process is faster in defects that treated topically with Omental and Hypericum extractions than in control defects that have not been treated topically by any agent. Furthermore, the healing process was faster in HD comparing to the OD.

Acknowledgments

Not applicable.

Funding statement

This study didn't receive any funding support

Declaration of Conflict of Interest

The author has no conflicts of interest to declare. I certify that I have no affiliations with or involvement in any organization or entity with any financial interest.

Ethical of approval

This experiment was approved by the Committee of Animal Welfare and Experiment Ethics - college of veterinary medicine, University of Duhok (VM2023/0607UD).

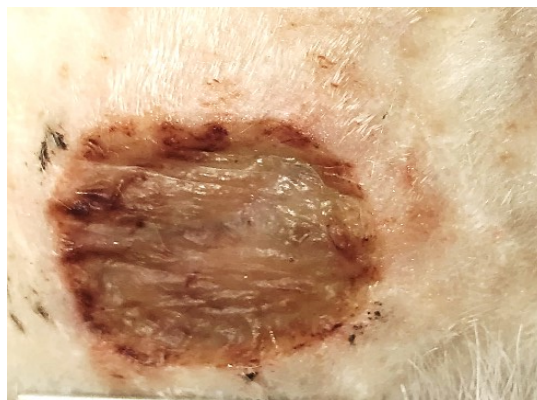


Fig. 1. The appearance of wound after 1 day in omental defect

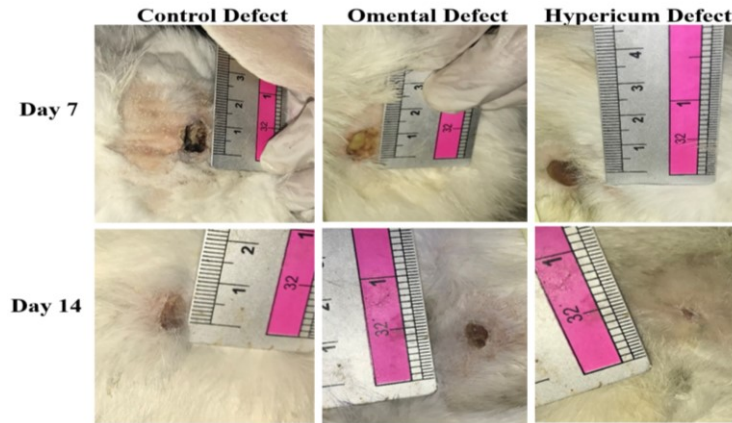


Fig. 2. Clinical observation of created defect on day 7 and 14 shows healing (contraction) rate

TABLE 1. Statistical comparison of wound contraction or healing rate of defects in three intervals among CD, OD, and HD. It was considered significantly different at P- value < 0.05.

Tukey's multiple comparisons test	Summary	Adjusted P Value
4 days		
Control Vs. Omentum	ns	>0.9999
Control Vs. Hypericum	ns	0.8162
Omentum Vs. Hypericum	ns	0.8162
7 Days		
Control Vs. Omentum	ns	0.1875
Control Vs. Hypericum	*	0.0132
Omentum Vs. Hypericum	ns	0.3096
14 Days		
Control Vs. Omentum	ns	0.3717
Control Vs. Hypericum	**	0.0024
Omentum Vs. Hypericum	*	0.0290

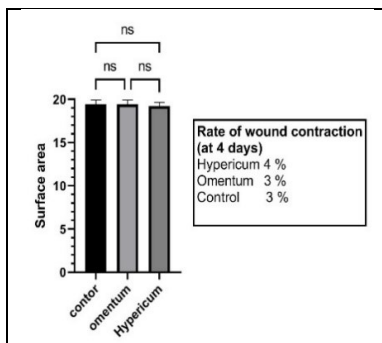


Fig. 3. Surface perimeter area of the defects and differences among CD, OD, and HD at 4 days intervals

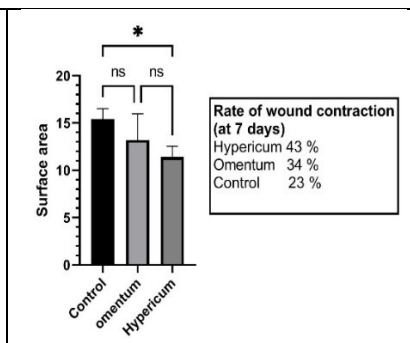


Fig. 4. Surface perimeter area of the defects and differences among CD, OD, and HD at 7 days intervals

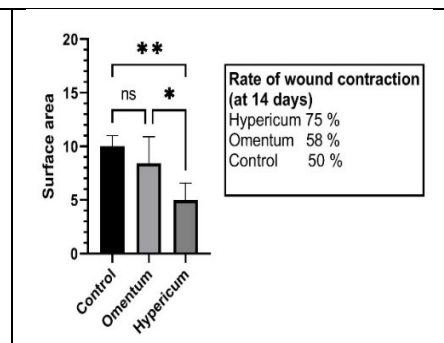


Fig. 5. Surface perimeter area of the defects and differences among CD, OD, and HD at 14 days intervals

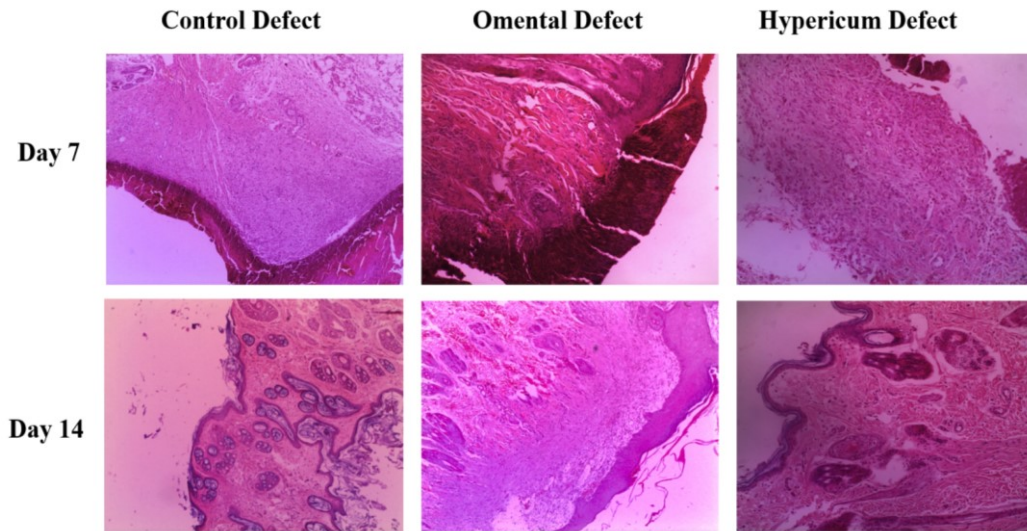


Fig. 6. Histopathological analysis of rabbit's skin biopsies taken at day 7, and 14 days interval of CD, OD, and HD by H & E at magnification 4x.

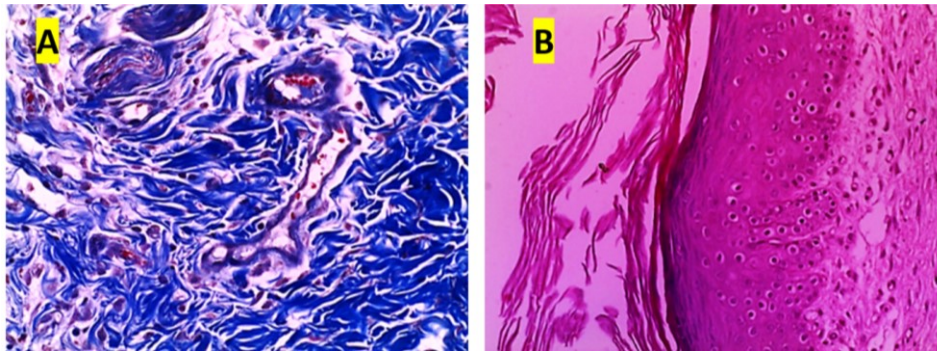


Fig. 7. (A) Histopathological analysis of collagen fiber characteristics of a biopsy taken from rabbit skin tissue (OD at day 7). Masson-trichrome staining of collagen (blue) at 20x magnification. (B) Histological analysis of a biopsy taken from rabbit skin tissue (HD at day 14) stained by H & E of, at 20magnification. shows the keratinocytes and keratosis.

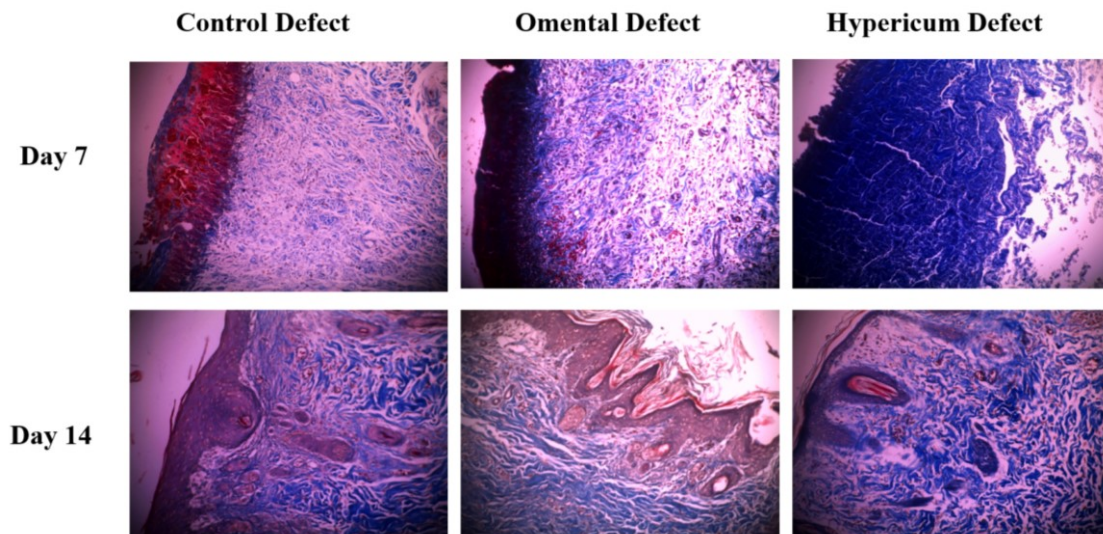


Fig. 8. Histopathological analysis of collagen fiber characteristics of biopsies of rabbit skin tissue. Masson-trichrome staining of collagen (blue) at 10x magnification

References

- Carvalho-Júnior, J.D.C., Zanata, F., Aloise, A.C., and Ferreira, L.M. Acellular dermal matrix in skin wound healing in rabbits - histological and histomorphometric analyses. *Clinics* (Sao Paulo, Brazil). **76**, e2066 (2020). <https://doi.org/10.6061/clinics/2021/e2066>
- Zeng, R., Lin, C., Lin, Z., Chen H., Lu, W., Lin, C., and Li, H. Approaches to cutaneous wound healing: basics and future directions. *Cell Tissue Res.*, **374**, 217–232 (2018). <https://doi.org/10.1007/s00441-018-2830->
- Yamaguchi, Y. and Yoshikawa, K. Cutaneous Wound Healing: An Update. *The Journal of Dermatology*, **28**, 521-534 (2001). <https://doi.org/10.1111/j.1346-8138.2001.tb00025.x>
- Kumar V., Khan A.A. and Nagarajan K. Animal Models for the Evaluation of Wound Healing Activity. *International Bulletin of Drug Research*, **3** (5), 93-107 (2013). https://www.researchgate.net/publication/274010528_ANIMAL_MODELS_FOR_THE_EVALUATION_OF_WOUND_HEALING_ACTIVITY
- Grada A., Mervis J. and Falanga V. Research Techniques Made Simple: Animal Models of Wound Healing. *J. Invest. Derma.* **138**, 2095-2105 (2018). <https://doi:10.1016/j.jid.2018.08.005>
- Rizzo, P., Altschmied, L., Ravindran, B.M., Rutten, T. and D'Auria, J.C. The Biochemical and Genetic Basis for the Biosynthesis of Bioactive Compounds in *Hypericum perforatum* L., One of the Largest Medicinal Crops in Europe. *Genes*. **11**(10)1210 (2020). <https://doi:10.3390/genes11101210>.
- Alahmad, A., Alghoraibi, I., Zein, R., Kraft, S., Dräger, G., Walter, J.G. and Scheper, T. Identification of Major Constituents of *Hypericum perforatum* L. Extracts in Syria by Development of a Rapid, Simple, and Reproducible HPLC-ESI-Q-TOF MS Analysis and Their Antioxidant Activities. *ACS Omega*. **7**, 13475–13493 (2022). <https://doi.org/10.1021/acsomega.1c06335>
- Linde, K. St. John's wort - an overview. *Forsch Komplementmed.* **16**, 146–155 (2009). <https://doi:10.1159/000209290>
- Süntar, I.P., Akkol, E.K., Yilmazer, D., Baykal, T., Kirmizibekmez, H., Alper, M. and Yeşilada, E. Investigations on the in vivo wound healing potential of *Hypericum perforatum* L. *J. Ethnopharmacol.*, **127**(2), 468–477 (2010). <https://doi:10.1016/j.jep.2009.10.011>
- Altan, A., Aras, M.H., Damlar, İ., Gökçe, H., Özcan, O. and Alpaslan, C. The effect of *Hypericum Perforatum* on wound healing of oral mucosa in diabetic rats. *Eur. Oral Res.*, **52**(3), 143-149(2018). doi: 10.26650/eor.2018.505.
- Budantsev, A.L., Prikhodko, V.A., Varganova, I.V. and Okovityi, S.V. Biological activity of *Hypericum perforatum* L. (Hypericaceae): a review. *Pharmacy & Pharmacology*, **9**(1), 17-31 (2021). <https://doi:10.19163/2307-9266-2021-9-1-17-31>
- Shah, S., Lowery, E., Braun, R.K., Martin, A., Huang, N., Medina, M., Sethupathi, P., Seki, Y., Takami M., Byrne, K., Wigfield, C., Love, R.B. and Iwashima, M. Cellular Basis of Tissue Regeneration by Omentum. *PLoS ONE*, **7**(6), e38368 (2012). <https://doi.org/10.1371/journal.pone.0038368>
- Fernandes, MESL, Peixoto, A.J.R., Campo, A.C.S., Borges, D.A., Pereira, G.O., Oliveira, J., Oliveira, L.M.S., Nogueira, V.A., Jorge, S.F. and Silva, M.F.A. Free omental graft without vascular microanastomosis in the cutaneous wound healing of rabbits. *Arq. Bras. Med. Vet. Zootec.*, **74**(5), 785-799 (2022). <http://dx.doi.org/10.1590/1678-4162-12700>.
- Litbarg, N.O., Gudehithlu, K.P., Sethupathi, P., Arruda, J.A. L., Dunea, G. and Singh, A.K. Activated omentum becomes rich in factors that promote healing and tissue regeneration. *Cell Tissue Res.*, **328**, 487–497 (2007). <https://doi.org/10.1007/s00441-006-0356-4>.
- Vernik, J. and Singh, A.K. Omentum: Power to Heal and Regenerate. *The International Journal of Artificial Organs*, **30**(2), 95-99 (2007). <https://doi.org/10.1177/039139880703000203>.
- Catsimpoilas, N. and Goldsmith, H.S. Angiogenicfactor Methods Of Extraction And Method For Producing Angiogenesis. United States Patent, Patent Number: 4,699,788. Date of Patent: Oct. 13, 1987. Trustees of Boston University, Boston, Mass. Online link: <https://patentimages.storage.googleapis.com/60/45/56/78beb99b369c9f/US4699788.pdf>
- Milosevic, T., Solujic, S. and Sukdolak, S. In Vitro Study of Ethanolic Extract of *Hypericum perforatum* L. on Growth and Sporulation of Some Bacteria and Fungi. *Turk. J. Biol.*, **31**, 237-241 (2007). <https://aj.tubitak.gov.tr/biology/issues/biy-07-31-4/biy-31-4-6-0705-13.pdf>.
- Ion, V., Ielciu, I., Cârje A-G., Muntean, D.L., Crişan, G. and Păltinean, R. *Hypericum* spp.—An Overview of the Extraction Methods and Analysis of Compounds. *Separations*, **9**(1), 17 (2022). <https://doi.org/10.3390/separations9010017>
- Mahmood, M. B. A Comparison between ketamine-xylazine and ketamine-midazolam or all of them to induce balance anesthesia in rabbits. *Iraqi Journal of Veterinary Sciences*, **36**(2), 499-506 (2022). <https://doi.10.33899/ijvs.2021.130618.1852>.
- Meredith, A. and Lord, B. BSAVA Manual of Rabbit Medicine. *British Small Animal Veterinary Association. England*, PP: 292 (2014). e-ISBN: 978 1 910443 21 7.
- Sibbald, R.G., Elliot, J.A., Persaud-Jalmangal, R., Goodman, L., Armstrong, D.G., Harley, C., Coelho, S., Xi, N., Evans, R., Mayer, D.O., Zhao, X., Heil, J., Kotru, B., Delmore, B., LeBlanc, K., Ayello, E.A., Smart, H., Tariq, G., Alavi, A. and Somayaji R. Wound bed preparation. *Adv Skin Wound Care*, **34** (4), 183 – 195 (2021). <https://doi.org/10.1097/01.ASW.0000733724.87630.d6>.

22. Kulyar, M.F., Ashfaq, K., Aqib, A.I., Duan, K., Asif, M., Bhutta, Z.A., Shoaib, M., Shabbir, S., Nawaz, S., Naseer, M.A., Sarwar, I., Akhtar, M., Chaudhry, A.S., Hussain, R., Hussain, H.I., Wu, Y. and Li, K. Enhanced Healing Activity of Manuka Honey and Nitrofurazone Composite in Full-Thickness Burn Wounds in the Rabbit Model. *Front. Vet. Sci.*, **9**, 875629 (2022).
23. Wang, P., Huang, B., Horng, H., Yeh, C. and Chen, Y. Wound healing. *Journal of the Chinese Medical Association*, **81**, 94-101 (2017). DOI:10.1016/j.jcma.2017.11.002
24. Hemmati, A.A., Rashidi, I. and Jafari, M. Promotion of Wound Healing by Hypericum Perforatum Extract In Rabbit. *Jundishapur Journal of Natural Pharmaceutical Products*, **2007**, 78-86 (2018).
25. Shao, Z.Q., Kawasuji, M., Takaji, K., Katayama, Y. and Matsukawa, M. Therapeutic Angiogenesis with Autologous Hepatic Tissue Implantation and Omental Wrapping. *Circ. J.*, **72**, 1894-1899 (2008). https://www.jstage.jst.go.jp/article/circj/72/11/72_CJ-08-0167/_pdf

مقارنة بين مستخلصات الثرب و هيبيركم بيرفورتم في شفاء الجروح الجلدية الاستتصالية ذات السمك الكامل في الأرانب

محمد سليم النجار*

قسم الطب والجراحة - كلية الطب البيطري - جامعة دهوك - العراق.

المستخلص

التحقق من التأثيرات السريرية والنسجية المرضية للتطبيق الموضعي لمستخلصات OMENTAL و HYPERICUM على شفاء جروح الجلد في الأرانب. تم تقسيم خمسة عشر أرنبًا إلى ثلاث مجموعات (4، 7، و14 يومًا). في كل حيوان، تم إنشاء ثلاث عمليات استئصال دائرية حوالي 2 سم، عيب التحكم (CD)، عيب (HD) HYPERICUM، وعيب الثرب (OD). وقد لوحظت عيوب سريريا بالنسبة لمعدلات الانكماش. تم أخذ خزعات للفحوصات النسيجية المرضية، وتم تلطيخ المقاطع بصبغة H&E وصبغة مایسون ثلاثية الألوان. وأظهرت المقارنة السريرية في فترة 4 أيام عدم وجود فروق ذات دلالة إحصائية بين ثلاث مجموعات. وبفاصل 7 أيام أظهر انخفاض كبير في حجم HD مقارنة مع CD عند قيمة P (0.0132)، في حين لم تك هناك فروق معنوية بين HD و OD بين لا CD ولا OD. في فترة 14 يومًا، كان الفرق بين HD و CD مهمًا للغاية (قيمة P 0.0024)، بين HD و OD كان كبيرًا (قيمة P 0.0290)، بينما لم يكن الفرق بين OD و CD مهمًا (قيمة P 0.3717). أظهرت الفحوصات النسيجية زيادة في عدد الخلايا الليفية والكولاجين ومعدل تكوين الأوعية الدموية على فترات 7 أيام والمزيد من إعادة الظهارة على فترات 14 يومًا في HD و OD مقارنةً بالقرص المضغوط. استنتج من النتائج أن هناك تأثيرات إيجابية لمستخلصي نبات HYPERICUM و OMENTAL على عملية الشفاء من خلال الزيادة.

الكلمات الدالة: المستخلص، عملية الشفاء، العرن، الثرب، الأرانب، استئصال الجلد.