



Protective Role of Pomegranate Seed Extract to Reduce Aflatoxin B1 Toxicity in Rabbits

Ehdaa O. Hamed¹, Hasnaa Osama^{2*}, Howayda A. Zohree³, Sultan F. Nagati⁴ and Momtaz A. Shahein⁵



CrossMark

¹ Department of Chemistry, Toxicology and Nutritional Deficiency, Toxicology Unit, Animal Health Research Institute (AHRI), Agriculture Research Center (ARC), EL-Fayoum Governorate laboratory, Egypt.

² Clinical Pharmacy Department, Faculty of Pharmacy, Beni-Suef University, Beni-suef, Egypt.

³ Department of Chemistry, Toxicology and Nutritional Deficiency, Toxicology Unit, Animal Health Research Institute (AHRI), Agriculture Research Center (ARC), Dokki, Giza, Egypt.

⁴ Department of Bacteriology, Animal Health Research Institute (AHRI), Agriculture Research Center (ARC), Egypt

⁵ Department of Virology, Animal Health Research Institute (AHRI), Agriculture Research Center (ARC), Egypt.

HIS investigation aimed to assess how Pomegranate Seed Extract (PSE) counteracted the negative impacts of Aflatoxin B1 Residue (AFB1) on liver health and antioxidant status in Aflatoxicated Rabbits. Twenty healthy male New Zealand rabbits (aged six weeks) were randomly divided into four experimental groups. Group I served as the negative control group without any treatment. Groups II and III were given AFB1 orally at (30 µg/kg.BW/day) for 21 days. On day one after Aflatoxin B1 administration, groups 3 and 4 were given 100 mg/kg of Pomegranate seed extract (PSE). The results showed that rabbits in groups 3 and 4 given 100 mg/Kg of PSE. Decreased levels of (ALT, AST, cholesterol, triglyceride, and total bilirubin), were observed in Group III which were significantly higher in the treated group II, indicating that PSE supplementation improved liver function tests. In addition, PSE supplementation significantly reduced Malondialdehyde (MDA) levels. Simultaneously, compared to the Aflatoxicated group, there has been a considerable rise in (superoxide dismutase enzyme (SOD), catalase (CAT), glutathione peroxidase (GPX), and reduced glutathione (GSH) enzymes. According to the findings, Pomegranate seed extract improved treated rabbits' liver function tests and antioxidant status through eliminating the detrimental effects of oxidative stress produced by Aflatoxin B1.

Keywords: Aflatoxin B1; Pomegranate seed; Antioxidant; Liver function; Rabbits

Introduction

Aflatoxin B1 (AFB1) is the most hazardous mycotoxin, with negative consequences for human and animal health. It is a secondary metabolite released by *Aspergillus flavus* and *Aspergillus parasiticus*, which grow on a large variety of feed and food commodities at any stage of growth,

harvesting, storage, and transportation [1]. The negative effects of Aflatoxin B1 on human and animal health include mutagenic, carcinogenic, teratogenic, and immunosuppressive effects. Therefore, Aflatoxin B1 (AFB1) is a significant source of concern [2]. The experimental evidence suggests that dietary aflatoxins are highly

associated with liver cancer incidence, particularly in developing countries [3-5]. Furthermore, it is well known that AFB1 induces liver-specific carcinogenicity by enhancing the substitution of thiamine (pyrimidine) with guanine (purine) at codon number 249 of the p53 gene [6]. Also, during the metabolism of AFB1 by hepatic enzymes [7], AFB1 can cause reactive oxygen species, (ROS) to be produced, resulting in oxidative stress and the oxidation of DNA, lipids, and proteins [8]. As a result, a variety of chemical, physical, and biological processes for inactivating or detoxifying aflatoxins in contaminated feedstuffs, have been proposed. Antioxidants are chemicals that inhibit the beginning of oxidative chain reactions, inhibiting the oxidation of lipids or other molecules [9].

Rabbits are raised in batteries in an intensive production method. So they are harmed by the cages (area, smell, micro-environment), and an increase in production may impact their physiological and hygienic health. Furthermore, through necrotic and apoptotic effects, the accumulation of free radicals inside their bodies will accelerate the rate of cell death [10].

Pomegranate trees (*Punica granatum* L.) are native to the (Middle East and India), and they have been used for medical purposes by ancient societies. Pomegranate has been used as an antiviral [11], antibacterial [12], and anticancer agent [13]. Furthermore, it is well known for its antioxidant capabilities in higher proportions than in most other fruit-related foods, which were once assumed to have the most antioxidants [14]. In addition, Pomegranate fruits have high polyphenol content [15].

Because of their antioxidant capabilities, natural botanicals have received much attention in the last year. Pomegranate contains phytochemical constituents rendering it more useful in traditional medicine for its antioxidant and antimicrobial properties [16]. Pomegranate seed is a by-product of the pomegranate juice industry that includes potent antioxidants, anti-inflammatory constituents, vitamin E, sterol, polyphenols, and estrogens [17].

This study aimed to discover if Pomegranate seed extract has any antioxidant or preventative capabilities against Aflatoxin B1-induced oxidative stress in rabbits.

Material and Methods

Samples of animal feed

One hundred animal feed samples (broiler feed, layer feed, yellow corn, compound feed, and hay) (twenty of each) were gathered from various animal farms in El -Fayoum governorate. Samples were placed into sterile plastic bags and delivered to the lab for analysis of aflatoxins as soon as possible.

Chemicals:

Aflatoxin B1 kit standard of 98% purity (Sigma-Aldrich St Louis, Mo, USA) product number A.6636. Pomegranate extract tablets (500 mg), standardized to a minimum of 400 mg ellagic acid, were purchased from Source Naturals. Inc., USA. A concentration of 100mg/1 ml was prepared by grinding and dissolving each tablet in 5 ml of distilled water. Serum biochemical parameters, ALT, AST, Total bilirubin, Cholesterol, and Triglyceride, were determined using calorimetry-based techniques by a commercially obtained kit (Bio-diagnostic, company, Egypt).

Liver tissue antioxidant parameters were investigated by measuring the levels of Malondialdehyde (MDA nmol/g tissue), reduced glutathione enzyme (GSH μ mol/mg protein), glutathione peroxidase (GPX U/mg protein), superoxide dismutase enzyme (SOD U/mg protein), and catalase (CAT U/mg protein), by colourimetric techniques using a commercially purchased kit (Bio-diagnostic, company, Egypt).

Experimental laboratory animals:

We used twenty healthy New Zealand rabbits (males) that were 45 days old and weighed between 800 and 1000 g. The rabbits were kept in wire cages, fed commercial pellet feed, and given unlimited access to water. The institutional ethics committee approved the study on the care and use of laboratory animals of ARC, AHRI (IACUC protocol number: ARC-AHRI-23-03).

Samples preparation and extraction:

To extract and prepare 10 gm of each sample for aflatoxin detection, an 80:20 mixture of acetonitrile and water was used. The samples were cleaned up using dispersed liquid-liquid micro-extraction, a very economical, fast, and sensitive method [18]. The samples were blinded and run at high speed/1 min; the filtrate was collected, and the extract passed through the fluted filter paper into a clean beaker.

Analysis of samples by HPLC

The filtrate was diluted with deionized water (40 mL) (Sigma Aldrich Company), well mixed, filtered through the filter (micro-fibre), and collected into a glass syringe barrel. The diluted extract passed through the Afla test p affinity column at a rate of one-two drops/second (2 mL = 0.2 g sample equivalent). Five mL of deionized water passed through the column at a rate of (2 drops / second), and repeated this process until air entered the column. The toxin quantified by HPLC-UV (model 1100-21) as described by Amirkhizi *et al.* [18].

Experimental protocol:

The ameliorative effects of Pomegranate seed extract on Aflatoxicosis-induced hepatotoxicity in rabbits were examined.

The animals were allocated at random to four experimental groups of five rabbits (each); as stated below, Group I was assigned as a negative control, receiving no treatment. Rabbits in groups II and III were administered AFB1 orally by stomach tube (30µg dissolved in 0.5 mL olive oil /kg. Bw for 21 days [19]. Pomegranate seeds extract tablets were supplied to groups III and IV on day one following the administration of AFB1 at 100 mg/Kg [20].

Clinical analysis

Animal liver function tests

Blood samples without anticoagulants were taken from the experimented rabbits after 21 days from the beginning of the experiment. Then, after centrifugation of blood samples at 3000 rpm/10 min, serum was separated for:

- Serum biochemical analysis for aspartate aminotransferase (AST) and alanine aminotransferase (ALT) was measured according

to the procedure of Reitman and Frankel [21]. Also, the examination of triglycerides was performed as stated by Fossati and Prencipe [22], cholesterol according to Allain *et al.* [23], and total bilirubin according to Walter and Gerade[24].

- Liver tissue antioxidant analysis for Catalase enzyme activity (CAT), peroxidation of lipids as malonaldehyde (MDA), reduced glutathione (GSH) and glutathione peroxidase (GPX) were also measured [25-28] as well as superoxide dismutase (SOD), described by Nishikimi *et al.*[29].

Pathological investigation

After ethical scarification, tissue specimens from livers were collected from separate groups; the specimen was preserved in 10% formalin. Alcohol was used for the dehydration of tissues that had been formalin-fixed. Then, tissues were cleared in xylene and embedded in paraffin wax [30] followed by staining 4-5 um sections with hematoxylin and eosin (H&E).

Statistical analysis:

Our collected data were reported as mean ±SE. All data were analyzed using (ANOVA) one-way analysis of variance using SPSS version 16.0 statistical software (SPSS, Inc, Chicago, IL,2007). The difference was statistically significant. When $P \leq 0.05$.

Results

Incidence of aflatoxin residues (ppb)

The results in a Table (1) indicated that the incidence of Aflatoxin residues in yellow corn and hay was 100%, 85% in broiler feed, 70% in layer feed, and 65% in compound feed samples. Moreover, the highest mean value of aflatoxin residues was detected in hay samples, followed

TABLE 1. Aflatoxin residues (ppb) determined in different animal feed samples (n=20)

Samples	Total aflatoxin residues (ppb)				
	Positive	% of positive	Minimum	Maximum	Mean ±SE
Broiler feed	17	% 85	0	50	16.20±3.2
Layer feed	14	%70	0	25	10.85±2.074
Compound feed	13	%65	0	50	15.43±3.74
Yellow corn	20	%100	20	60	38.10±2.793
Hay	20	%100	40	200	109.25±13.403

The permissible limit of Aflatoxins is 20 ppb according to FAO (1995) and FDA (1999).

TABLE 2. The mean values of serum biochemical parameters in different treated groups of rabbits

Serum Biochemical Parameters	Groups			
	Group I (Negative Control)	Group II (AFB1)	Group III (AFB1+PSE)	Group IV (PSE)
ALT (U/L)	26.61±1.96	74.29±2.94 ^a	55.34±2.71 ^{ab}	24.78±1.73 ^c
AST (U/L)	55.52±1.34	100.2±1.76 ^a	85.08±1.21 ^{ab}	54.91±1.61 ^{bc}
Cholesterol (mg/dl)	81.06±1.95	110.120±2.72 ^a	87.33±1.26 ^b	79.98±2.82 ^b
Triglyceride (mg/dl)	154.18 ±2.66	195.88±3.79 ^a	168.04±3.63 ^{ab}	143.11±2.74 ^{bc}
Total bilirubin(mg/dl)	0.948±0.031	1.463±0.024 ^a	1.138±0.061 ^{ab}	0.853±0.011 ^{bc}

Values are Mean ±SE. AFB1: Aflatoxin B1; PSE: Pomegranate seed-extract

^a denotes significant difference from the mean estimate of the control group at the 0.05 level.

^b denotes significant difference from the mean estimate of the AFB1 group at the 0.05 level.

^c denotes significant difference from the mean estimate of the AFB1+PSE group at the 0.05 level.

by yellow corn, broiler feed, compound feed, and layer feed.

Serum biochemical parameters

The mean serum ALT and AST levels (U/L) findings are illustrated in Table (2), These data analyses demonstrated that aflatoxin B1 in treated group II caused a significant ($P \leq 0.05$) increase in serum ALT and AST activity compared to the control group. While the third group, which got aflatoxin together with Pomegranate seed extract as (an antioxidant), exhibited a significant decrease in serum ALT and AST levels compared to the aflatoxins-treated group. There was no statistically significant difference between group IV and the control group. Therefore, data confirmed that PSE improved the blood levels of ALT and AST in rabbits given PSE.

Furthermore, data analysis revealed that triglyceride, cholesterol, and total bilirubin levels in the Aflatoxicated group II-increased ($P \leq 0.05$) significantly compared to the control group. The triglyceride, cholesterol, and total bilirubin levels in -group III, which got aflatoxin B1 + PSE, decreased significantly compared to group II. While group IV had, a non-significant reduction compared to the control group. Thus, results established that PSE reduces serum triglyceride, cholesterol, and total bilirubin levels in rabbits supplemented with PSE.

Liver tissue antioxidant status

The current results listed in the Table (3)

demonstrated a significant ($P \leq 0.05$) increase in Malondialdehyde (MDA), the biomarker of lipid peroxidation, in the AFB1-treated group when compared to the control group. Superoxide dismutase enzyme (SOD), glutathione peroxidase (GPX), reduced glutathione (GSH) and catalase (CAT) levels significantly decreased in the aflatoxin-treated group II as compared to the control group. While group III, which received aflatoxin plus PSE, showed a significant decrease in GSH, GPX and CAT levels compared with the control group. Additionally, group IV showed a decrease in MDA levels in rabbits supplemented with PSE at 100 mg/kg compared to groups II and III, and the difference was significant ($p \leq 0.05$). The GSH, GPX and SOD in the liver tissue of rabbit's in-group 4 were significantly different compared to that in-group III.

Histopathological investigations

The histopathological investigations of livers are presented in Figs. 1, 2, 3, and 4. Liver histology of the control group showed normal histo-morphological structures (Fig.1).

The liver histology of group II which received Aflatoxin B1 showed degenerative changes in cytoplasm of the hepatocyte (hydropic degeneration), fibrosis and thickening of the portal area, inflammatory cells infiltration, and apoptosis in the surrounding cells (Fig.2).

The liver of rabbit's in-group III which received Aflatoxin B1 + PSE) showed low inflammatory

TABLE 3. The effect of aflatoxin and its co-administration with pomegranate seed extract antioxidant biomarkers in liver tissue (n=5 in each group).

Groups	Group I (Negative Control)	Group II (AFB1)	Group III (AFB1+PSE)	Group IV (PSE)
MDA(nmol/gtissue)	6.43 ±0.24	14.62± 0.83 ^a	10.42 ±0.16 ^{ab}	6.79 ±0.29 ^{bc}
GSH(μmol/mgprotein)	398.40± 3.63	314.80± 10.54 ^a	352.91± 9.31 ^{ab}	401.33± 6.73 ^{bc}
GPX(U/mg protein)	16.21± 0.46	11.37 ±0.62 ^a	13.80± 0.57 ^{ab}	18.22 ±0.38 ^{abc}
SOD(U/mg protein)	132.82 ±6.21	115.35± 2.54 ^a	127.21 ±3.62 ^b	139.44 ±7.61 ^{bc}
CAT(U/mg protein)	8.23±0.08	6.17±0.06 ^a	7.85±0.19 ^{ab}	11.63±0.34

Values are Mean±SE. AFB1: Aflatoxin B1; PSE: Pomegranate seed-extract; MDA: Malondialdehyde; GSH: Reduced Glutathione; GPX: Glutathione peroxidase; SOD: Superoxide dismutase; CAT: Catalase enzyme

^a denotes significant difference from the mean estimate of the control group at the 0.05 level.

^b denotes significant difference from the mean estimate of the AFB1 group at the 0.05 level.

^c denotes significant difference from the mean estimate of the AFB1+PSE group at the 0.05 level.

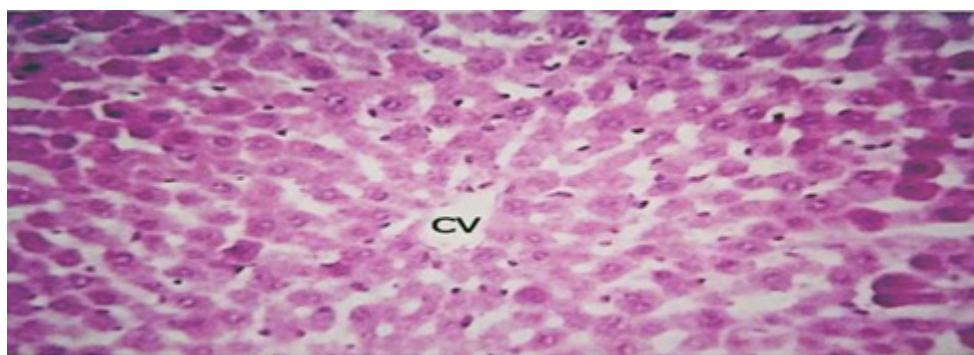


Fig. 1. Liver histology of Group I (the negative control group). CV: central vein. Central vein in control group is normal H.E.X80.

cell infiltration, and mild hydropic degeneration with mild dilatation in the central vein (Fig.3). The liver of rabbit's in-group IV received only PSE restored typical histo-morphological structures (Fig.4).

Discussion

Incidence of Aflatoxin residues

From several farms in El-Fayoum Governorate, 100 samples of broiler feed, layer feed, compound feed, yellow corn, and hay were gathered. Aflatoxin residues were found in the analyzed samples, as stated in the Table (1). Aflatoxin residues were identified in all animal diets, with an average of 109.250013.403 ppb in hay and 38.1002.793 ppb in yellow corn, respectively, with incidence (85%) in broiler feed,

(70%) in layer feed, and (65%) in compound feed.

Hassan et al. [31] stated that the incidence of Aflatoxin residues in hay and yellow maize was (100 %) which agrees with our results. In addition, our results were supported by those of Alshwabkeh et al. [32], who discovered that the mean value of Aflatoxin residue in layer grower ration was 10.15± 9.39 ppb. While Mahmoud and Mohamed[33] determined that the average Aflatoxins level in the broiler ration was 17.22±20 ppb. Moreover, Hassan et al.[34] indicated that the percentage of Aflatoxin content in rabbit feed selected samples from rabbit farming in the El-Menofia governorate was 60%.

The percentage of Aflatoxin found in a compound feed sample recorded by Tipu et al.

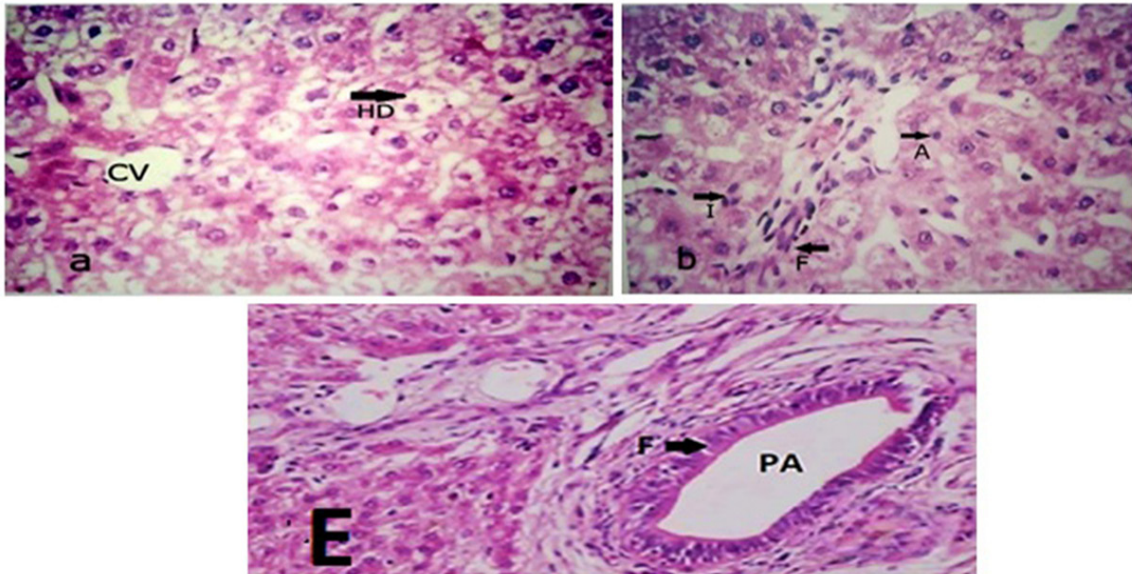


Fig. 2. Degenerative changes in cytoplasm of the hepatocyte (hydropic degeneration) of group II which received Aflatoxin B1 (a), fibrosis and thickening of the portal area, inflammatory cells infiltration, and apoptosis in the surrounding cells (b&E). CV, central vein; HD, hydropic degeneration; F, fibrosis; I, infiltration of inflammatory cells; A, apoptosis; PA, the portal area. H.E.X80.

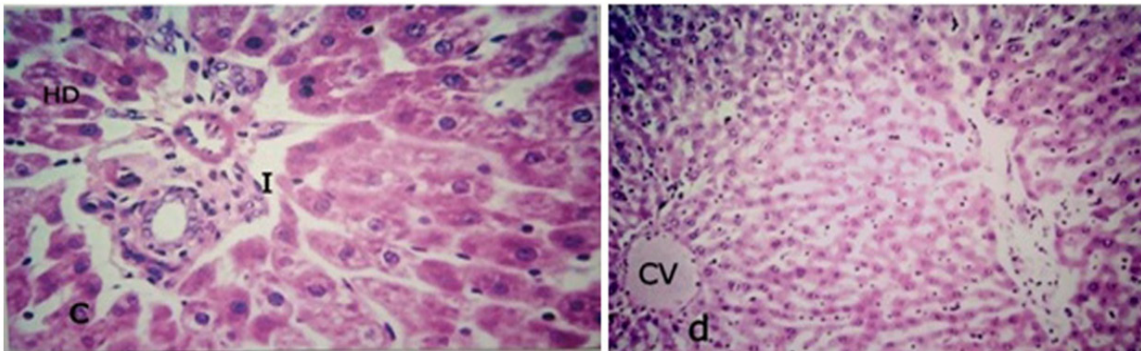


Fig. 3. The liver of rabbit's in-group III (which received Aflatoxin B1 + PGSP). (I), low inflammatory cell infiltration, and HD, mild hydropic degeneration (c); CV, central vein showed mild dilatation (d) H.E.X80

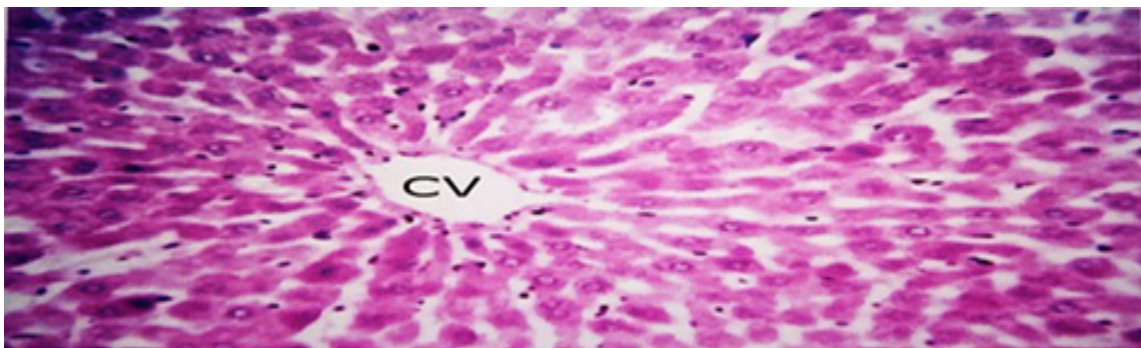


Fig. 4. The liver of the rabbit's in-group IV (taken only PSE) restored typical histo-morphological structures. H&E. CV, central vein in group IV is normal. H.E.X80.

was only 21% [35]. In addition, Kotinagu et al. [36] had an incidence of Aflatoxin residue of 33% in compound feed samples, which was lower than the incidence obtained in our results. Of all Aflatoxins found in feed and food, Aflatoxin B1 is the most prevalent [36] and widespread [37] of all Aflatoxins found in feed and food. It is responsible for about 75% of the contamination worldwide.

In developing countries, there is a correlation between liver cancer occurrence and the consumption of Aflatoxins in diet [3-5]. Because of their potential for toxicity, immunosuppression, mutagenicity, carcinogenicity, teratogenicity, and neurotoxicity, Aflatoxin contamination in animal feeds needs a global concern [39]. In addition, the binding of aflatoxins to nucleic acids impairs protein synthesis in the body [35]. Twenty ppb is the permissible level of aflatoxins in feeds and foods set by the Food and Drug Administration (FDA) [40]. However, in the current study, Aflatoxins residues in hay and yellow corn feed exceeded those of the FDA [40] and the Food and Agriculture Organization of the United Nations (FAO) [41]. Additionally, Aflatoxins residues exceeded the permissible limit of 15 ppb recommended by the World Health Organization (WHO) [42]. Thus, its consumption may pose a health risk for animals.

Liver function status

The biochemical analysis of treated rabbits' serum shown in the Table. (2), indicated a significant increase in (ALT and AST) activities, cholesterol, triglyceride, and total bilirubin concentrations in the Aflatoxin B1 group (II). There are similarities between the attitude expressed in this study and those described by Mogda *et al.* and Hassan *et al.* [43, 31]. According to histopathological findings, necrosis of hepatic cells may have released liver enzymes into the bloodstream [44]. Aflatoxin's hepatic toxicity is attributed to the epoxide, an active metabolite in the liver that covalently binds to DNA and consequently may affect structural and enzymatic function [45, 46].

The third group received aflatoxin and PSE as (an antioxidant), showing a significant decrease in serum ALT and AST levels. Furthermore, no statistically significant difference was presented between group IV and the control group. The data analysis revealed that the levels of triglycerides, cholesterol, and total bilirubin in group II exposed to aflatoxins rose significantly ($P \leq 0.05$) compared to the control group. On

the other hand, triglyceride, cholesterol, and total bilirubin levels decreased significantly in group III, which received Aflatoxin B1 + PSE, compared to group II. In contrast, group IV had a non-significant difference compared to the control group. Therefore, our results indicate that PSE is protective against Aflatoxin B1-induced disorders after its administration, affecting liver enzymes (ALT and AST), cholesterol, triglycerides, and total bilirubin.

Our results support those of El-Gindy, 2018, who found that all diets containing *Punica granatum* peel improved serum total cholesterol concentrations. In addition, Pomegranate seed reduced serum cholesterol via the activity of hepatic cholesterol 7-hydroxylase [47]. Furthermore, Ibrahim *et al.* [48], reported that *Punica granatum* by-products' supplements at 1.0, 1.5, and 2.0 % resulted in lower total cholesterol levels than those of experimental rabbits assigned for the control diet [48]. Hassan *et al.* [17] also demonstrated that feeding a diet supplemented with Pomegranate seed extract to rabbits at 100, 150, and 200 mg/kg diet resulted in lower total cholesterol and lipid concentrations [17].

Kolhe *et al.* [49], discovered that chronic Aflatoxicosis causes hyperbilirubinemia in rabbits which might be linked to hepatocellular damage and hemolysis [49]. Aflatoxin significantly elevated bilirubin levels and caused severe cholesterolemia, both of which could have been produced by hepatotoxicity [50].

Antioxidant status

In the homogenate of rabbit liver tissues, AFB1 raised the MDA concentration while decreasing the GSH, SOD, CAT, and GPX. It is proposed that the development of cell damage was driven by increased MDA as an oxidative stress system and decreased CAT and GPX activities as a defensive mechanism [51]. Other investigations discovered that AFs induced liver cirrhosis due to decreased GSH reserves [43]. The reduced enzyme activities and higher MDA levels caused by AFB1 might be attributed to impaired cell and tissue ability and nitric oxide generation in liver cells [52].

Regarding rabbits' antioxidant markers and enzymes, our findings indicate that PSE supplements increase SOD, GSH, GPX and CAT enzyme activity and decrease MDA levels as a lipid peroxidation index. These results agree with Naji *et al.* [53]. Therefore, increased activity of GSH, GPX, SOD, and CAT could have improved

the ability to diminish free radicals caused by the oxidative stress of Aflatoxin B1. Consequently, a reduction in MDA concentration is associated with increased antioxidant enzymatic activity due to PSE supplementation. This finding is corroborated by the ideas of Hassan *et al.* [54], who suggested an increase in SOD, GSH, and CAT enzymes activity, and a decrease in MDA content in the case of a rabbit's diet supplemented by PSE.

Hassan *et al.* (2021) stated that the administration of PSE antagonizes the effects of AFB1 as it contains many biologically active compounds such as minerals (Zn and Se), vitamins (C and E), and (total phenols and flavonoids) [54]. The identified vitamins, including vitamins (C, E, and A) in the peels and seeds of the pomegranate plant, are well-known for their powerful antioxidant capabilities [55].

Selenium can protect cells from damage induced by oxidative stress through the enzymatic activity of GSH-Px, (an enzyme that induces the reduction of both hydrogen peroxide and organic peroxides), and in turn, aids in preventing lipid peroxidation [56, 57]. Pomegranate seeds' antioxidant activity has been attributed to their constituents of ascorbic acid and phenols [58]. Tannins in pomegranate are the most significant polyphenols with potent free radical scavenging properties [59]. Flavonoids, including quercetin, catechin, catechin-gallate, and kaempferol, enhance the effects of antioxidant enzyme and decline free radicals [60].

Histological demonstration.

This study also demonstrated that AF could induce pathological changes in the livers of rabbits exposed to it. These pathological changes ranged from severe hydropic degeneration to cell necrosis and apoptosis. In addition, there was fibrosis in the portal area and inflammatory cell infiltration (Fig. 2). Similar pathological liver lesions were observed in rabbits orally administered AF [61, 19]. These pathological features could be attributed to the high production of ROS by AFB1, which leads to damage of cell compounds and membranes, and consequently, cell function impairment and cell lysis [62, 63]. In addition, a possible explanation for these described pathological outcomes in liver tissue could be traced back to AF's ability to cause remarkable changes in the stability of the lysosomal membrane, which in turn causes altered permeability of hepatocytes. Furthermore,

the liver's cytochrome P450 enzymes may have converted AF into its active metabolites, resulting in cell damage. The biochemical changes in the liver confirmed these effects [64].

In PSE, there was an improvement in hepatic cell morphology in the treated group, with mild degenerative changes, low inflammatory cell infiltration, and mild central vein dilatation (figure.3). Ali *et al.* [65] explained the hepato-protective potential of Pomegranate seed extract on liver cells by lowering oxidative stress and inflammation [65]. In addition, Pfohl *et al.* [66] investigated the hepato-protective, and anti-inflammatory effects of *Punica granatum* fruit extract phenolic compounds [66]. Therefore, PSE has been widely studied as an antioxidant due to its high vitamin C content (3.13mg/100g), vitamin E (1.45 mg/100g), zinc (5.60 mg/100g), selenium (0.22 mg/100g), phenols (0.27%), and flavonoids (0.21%) [54]. So, Pomegranate seed is regarded as one of the essential phytochemicals with antioxidant properties. Therefore, our results demonstrated that supplementation with PSE was statistically beneficial in reducing or preventing the harmful effect of Aflatoxin B1 on liver function biomarkers. Additionally, it could ameliorate the pathological changes of hepatic tissues in rabbits intoxicated with Aflatoxin B1.

Conclusion

The current study found that Aflatoxin B1 harms the hepatic tissues' structure and function. A pomegranate seed extract has a positive impact on lowering the adverse effects of Aflatoxin on liver function and antioxidant status in exposed rabbits.

Acknowledgment

None

Conflicts of interest

The authors declared no competing interests.

Funding statement

The authors declare that no funds, grants, or other support were received during the preparation of this manuscript.

References

1. Henry, T. and Iwen, P.C. Hinrichs SH Identification of *Aspergillus* species using internal transcribed spacer regions 1 and 2. *J. Clin. Microbiol.*, **38**, 1510-1515(2000). <https://doi.org/10.1128/JCM.38.4.1510-1515.2000>.

2. Fernández Pinto, V., Patriarca, A., Locani, O. and Vaamonde, G. Natural co-occurrence of aflatoxin and cyclopiazonic acid in peanuts grown in Argentina. *Food Addit. Contam.*, **18**(11), 1017–1020 (2001). <https://doi.org/10.1080/02652030110057125>.
3. Food and Drug Administration (FDA). Conference on mycotoxins in animal feeds, grains and food related to human and animal health. Rockville, Maryland. (2000).
4. Bhatnagar, D., Yu, J. and Ehrlich, K.C. Toxins of Filamentous Fungi. In: Breitenbach M, Cramer R, Lehrer SB (eds) *Chemical Immunology and Allergy. KARGER, Basel*, pp 167–206 (2002). <https://doi.org/10.1159/000058867>.
5. Refai, M.K. and Hassan, A.A. Monograph On Mycotoxigenic Fungi and Mycotoxins in Foods and Feeds with Synopsis on studies done by authors on mycotoxigenic fungi and mycotoxins in foods and feeds, *Cairo, Academic edu/Mohamed Refai*. 191 pages (2013).
6. Verma, J., Johri, T.S., Swain, B.K. and Ameena, S. Effect of graded levels of aflatoxin, ochratoxin and their combinations on the performance and immune response of broilers. *Br. Poult. Sci.*, **45**,512–518 (2004). <https://doi.org/10.1080/00071660412331286226>.
7. Kanbur, M., Eraslan, G., Sarica, Z.S. and Aslan, Ö. The effects of evening primrose oil on lipid peroxidation induced by subacute aflatoxin exposure in mice. *Food Chem. Toxicol.*, **49**,1960–1964 (2011). <https://doi.org/10.1016/j.fct.2011.05.006>.
8. Mary, V.S., Theumer, M.G. and Arias, S.L. Rubinstein HR Reactive oxygen species sources and biomolecular oxidative damage induced by aflatoxin B1 and fumonisin B1 in rat spleen mononuclear cells. *Toxicology*, **302**,299–307(2012). <https://doi.org/10.1016/j.tox.2012.08.012>.
9. Velioglu, Y.S., Mazza, G., Gao, L. and Oomah, B.D. Antioxidant Activity and Total Phenolics in Selected Fruits, Vegetables, and Grain Products. *J. Agric. Food Chem.*, **46**,4113–4117(1998). <https://doi.org/10.1021/jf9801973>.
10. Li, S., Tan, H-Y., Wang, N., Zhang, Z.J., Lao, L., Wong, C.W. and Feng, Y. The Role of Oxidative Stress and Antioxidants in Liver Diseases. *Int. J. Mol. Sci.*, **16**,26087–26124 (2015). <https://doi.org/10.3390/ijms161125942>.
11. Haidari, M., Ali, M., Ward Casscells, S. and Madjid, M . Pomegranate (*Punica granatum*) purified polyphenol extract inhibits influenza virus and has a synergistic effect with oseltamivir. *Phytomedicine Int. J. Phytother. Phytopharm.*, **16**,1127–1136 (2009). <https://doi.org/10.1016/j.phymed.2009.06.002>.
12. Hussin, W.A. and El-Sayed, W.M. Synergic Interactions between Selected Botanical Extracts and Tetracycline against Gram Positive and Gram Negative Bacteria. *J. Biol. Sci.*, **11**,433–441(2011). <https://doi.org/10.3923/jbs.2011.433.441>.
13. Syed, D., Chamcheu, J-C., Adhami, V. and Mukhtar, H. Pomegranate Extracts and Cancer Prevention: Molecular and Cellular Activities. *Anticancer Agents Med. Chem.*, **13**(8)1149–1161 (2013). <https://doi.org/10.2174/1871520611313080003>.
14. Li, Y., Guo, C., Yang, J., Wei, J., Xu, J. and Cheng, S. Evaluation of antioxidant properties of pomegranate peel extract in comparison with pomegranate pulp extract. *Food Chem.*, **96**, 254–260 (2006). <https://doi.org/10.1016/j.foodchem.2005.02.033>.
15. Elfalleh, W.N., Tlili, N., Nasri, N., Nasri, Y., Yahia, M. and Hannachi, H. Antioxidant capacities of phenolic compounds and tocopherols from Tunisian pomegranate (*Punica granatum*) fruits. *J. Food Sci.*, **76**,C707-713(2011). <https://doi.org/10.1111/j.1750-3841.2011.02179>.
16. Doostan, F., Vafafar, R., Zakeri-Milani, P., Pouri, A., Afshar, R.A. and Abbasi, M.M. Effects of pomegranate (*Punica granatum* L.) seed and peel methanolic extracts on oxidative stress and lipid profile changes induced by methotrexate in rats. *Advanced Pharmaceutical Bulletin*, **7**(2), 269-274 (2017).
17. Hassan, F.A., Ibrahim, M.R.M. and Arafa, S.A. Effect of dietary pomegranate by-product extract supplementation on growth performance, digestibility, and antioxidant status of growing rabbit. *Trop. Anim. Health Prod.*, **52**,1893–1901 (2020). <https://doi.org/10.1007/s11250-020-02201-0>.

18. Amirkhizi, B., Arefhosseini, S.R., Ansarin, M. and Nemati, M. Aflatoxin B1 in eggs and chicken livers by dispersive liquid-liquid microextraction and HPLC. *Food Addit. Contam. Part B Surveill.*, **8**, 245–249 (2015). <https://doi.org/10.1080/19393210.2015.1067649>.
19. Orsi, R.B., Oliveira, C.A.F., Dilkin, P., Xavier, J.G., Direito, G.M. and Correa, B. Effects of oral administration of aflatoxin B1 and fumonisin B1 in rabbits (*Oryctolagus cuniculus*). *Chem. Biol. Interact.*, **170** (3), 201–208 (2007). <https://doi.org/10.1016/j.cbi.2007.08.002>.
20. Omer, R. M., Baban, D. A. and Ahmed, B. M. Effect of Oral Supplementation for Rabbits of Pomegranate seed Extract on Some Serum Biochemical Parameters in Relation to oral Inflammation, oxidative stress, and wound healing. *Journal of Baghdad College of Dentistry*, **31**(2), 14-19 (2019).
21. Reitman, S. and Frankel, S. A colorimetric method for the determination of serum glutamic oxalacetic and glutamic pyruvic transaminases. *American Journal of Clinical Pathology*, **28**(1), 56-63 (1957).
22. Fossati, P. and Prencipe, L. Serum triglycerides determined calorimetrically with an enzyme that produces hydrogen peroxide. *Clin. Chem.*, **28**(10), 2077-2080 (1982). PMID: 6812986.
23. Allain, C.C., Poon, L.S., Chan, C.S., Richmond, W. and Fu, P.C. Enzymatic determination of total serum cholesterol. *Clin. Chem.*, **20** (4), 470–475 (1974).
24. Walters, M.I. and Gerarde, H.W. An ultramicromethod for the determination of conjugated and total bilirubin in serum or plasma. *Microchem. J.*, **15**, 231–243 (1970). [https://doi.org/10.1016/0026-265X\(70\)90045-7](https://doi.org/10.1016/0026-265X(70)90045-7)
25. Ohkawa, H., Ohishi, N. and Yagi, K. Assay for lipid peroxides in animal tissues by thiobarbituric acid reaction. *Anal. Biochem.*, **95**,351–358 (1979). [https://doi.org/10.1016/0003-2697\(79\)90738-3](https://doi.org/10.1016/0003-2697(79)90738-3).
26. Atmaca, G. Antioxidant effects of sulfur-containing amino acids. *Yonsei Med. J.*, **45**, 776–788 (2004).
27. Ellman, G.L. Tissue sulfhydryl groups. *Arch. Biochem. Biophys.*, **82**,70–77 (1959). [https://doi.org/10.1016/0003-9861\(59\)90090-6](https://doi.org/10.1016/0003-9861(59)90090-6).
28. Paglia, D.E. and Valentine, W.N. Studies on the quantitative and qualitative characterization of erythrocyte glutathione peroxidase. *J. Lab. Clin. Med.*, **70**,158–169 (1967).
29. Nishikimi, M., Appaji Rao, N. and Yagi, K. the occurrence of superoxide anion in the reaction of reduced phenazine methosulfate and molecular oxygen. *Biochem. Biophys. Res. Commun.*, **46**,849–854 (1972). [https://doi.org/10.1016/S0006-291X\(72\)80218-3](https://doi.org/10.1016/S0006-291X(72)80218-3).
30. Suvarna, K. S., Layton, C. and Bancroft, J. D. (Eds.). Theory and practice of histological techniques (7th Ed). Elsevier Churchill Livingstone. 573 pages (2013).
31. Hassan, A. Atef, Mogda, K. Mansour, Essam, M. Ibrahim, Rasha M.H., Naglaa Sayed El-Ahl, Al-Kalamawey, M., El Kattan, Y.A. and Ali, M.A. Efficacy of Zinc Oxide Nanoparticles and Curcumin in Amelioration the Toxic Effects in Aflatoxicated Rabbits. *Int.J. Curr. Microbiol. App. Sci.*, **5**(12), 795-818 (2016). doi: <http://dx.doi.org/10.20546/ijcmas.2016.512.090>.
32. Alshawabkeh, K., Alkhalailah, N.I., Abdelqader, A., Al-Fataftah, A.R.A. and Herzallah, S.M. Occurrence of aflatoxin B1 in poultry feed and feed ingredients in Jordan using ELISA and HPLC. *American-Eurasian Journal of Toxicological Sciences*, **7**(4), 316-320 (2015).
33. Mahmoud, E. and Mohamed, A. Incidence and concentration of Aflatoxin B1 and Ochratoxin A on broilers ration in Dakahlia Governorate Egypt. *Assiut Veterinary Medical Journal*, **62**(148), 48-51 (2016). <https://DOI:10.21608/avmj.2016.169209>.
34. Hassan, A. Atef, Mogda, K. Mansour, Essam, M. Ibrahim, Mahmoud M. Arafa, Ola, F.A. Talkhan and Noha, H. Oraby. Protective and detoxifying effects of selenium nanoparticles and thyme extract on the aflatoxin B1 in rabbits. *Egypt. J. Agric. Res.*, **100**(3),284-293 (2022). doi:10.21608/ejar.2022.111578.1214.
35. Tipu, M.A., Anjum, R., Anwar, S., Tahir, H., Akhtar, M. and Din, S.G.M. Trends of Aflatoxin in livestock feed and various feed ingredients in Pakistan. *Pakistan Journal of Science*, **72**(4), 4 (2020).

36. Kotinagu, K., Mohanamba, T. and Kumari, L.R. Assessment of aflatoxin B1 in livestock feed and feed ingredients by high-performance thin layer chromatography. *Vet. World*, **8**,1396–1399 (2015). <https://doi.org/10.14202/vetworld.2015.1396-1399>.
37. Khayoon, W.S., Saad, B., Yan, C.B., Hashim, N.H., Ali, A.S.M., Salleh, M.I. and Salleh, B. Determination of aflatoxins in animal feeds by HPLC with multifunctional column clean-up. *Food Chem.*, **118**, 882–886 (2010). <https://doi.org/10.1016/j.foodchem.2009.05.082>.
38. Mostrom, M.S. and Jacobsen, B.J. Ruminant Mycotoxicosis. *Vet. Clin. North. Am. Food Anim. Pract.*, **27**,315–344 (2011). <https://doi.org/10.1016/j.cvfa.2011.02.007>.
39. Lee, N. A. and Rachmawati, S. A rapid ELISA for screening aflatoxin B1 in animal feed and feed ingredients in Indonesia. *Food and Agricultural Immunology*, **17**(2), 91-104 (2006).
40. Food and Drug Administration, FDA. Action levels for poisonous or deleterious substances in human food and animal feed. (1999). Download from [Http://Vm.cfsan.fda.gov/ird/fdaact.html](http://vm.cfsan.fda.gov/ird/fdaact.html) on 7/8/1999.
41. Food and Agriculture Organization of the United Nations FAO. Food and Nutrition paper. Worldwide Regulation of Mycotoxins, Advanced Copy (1995).
42. World Health Organization, WHO Environmental health criteria Mycotoxins, Geneva, 86-98. Geneva, 86-98 (1979).
43. Mogda K. Mansour, Hanan A. Tag El- Din, Safaa M. Abou El Soud and Mostafa A. Abo Norag . Trial to ameliorate the toxic effect of Aflatoxins in the laboratory animals. *J. Vet. Sci.*, **1**, 15-25 (2014).
44. Lynch, G.P., Shalkop, W.T., Jacoby, N.M., Smith, D.F. and Miller, R.W. Responses of Dairy Calves to Oral Doses of Aflatoxin. *J. Dairy Sci.*, **54**,1688–1698 (1971). [https://doi.org/10.3168/jds.S0022-0302\(71\)86090-3](https://doi.org/10.3168/jds.S0022-0302(71)86090-3).
45. Netke, S.P., Roomi, M.W., Tsao, C. and Niedzwiecki, A. Ascorbic Acid Protects Guinea Pigs from Acute Aflatoxin Toxicity. *Toxicol. Appl. Pharmacol.*, **143**,429–435(1997). <https://doi.org/10.1006/taap.1996.8091>.
46. Culler, J.M. and Newbern, P.M. the toxicity of aflatoxin human health, veterinary and agricultural significance. 2nd Ed., *Aca-demic Press*, Philadelphia. (1994)
47. El-Gindy, Y.M. Hematological and antioxidant status of pregnant rabbits at third trimester as affected by pomegranate peels under heat stress condition. *Egypt Poul. Sci. J.*, **381**, 1-10 (2018).
48. Ibrahim, M.R.M., Arafa, S.A., Hassan, F.A. and, Zaki, E.E. Utilization of pomegranate (*Punica granatum L.*) byproduct powder as a natural growth promoter in growing rabbit diets. *Egypt J. Rabbit Sci.*, **27**,197–217 (2017). <https://doi.org/10.21608/ejrs.2017.46568>.
49. Kolhe, A.S., Verma, R.J. and Bhole, R.V. Effect of Dietary Aflatoxin on Bile content of Gall Bladder and Bilirubin concentration During Aflatoxicosis in Rabbits. *Res. Link.*, **32**(V 7) 21 (2006).
50. Ismail, I.E., Farag, M.R., Alagawany, M., Mahmoud, H.K. and Reda, F.M. Efficacy of some feed additives to attenuate the hepatorenal damage induced by aflatoxin B1 in rabbits. *J. Anim. Physiol. Anim. Nutr.*, **104**,1343–1350 (2020). <https://doi.org/10.1111/jpn.13359>.
51. Benkerroum, N. Chronic and acute toxicities of aflatoxins: Mechanisms of action. *International Journal of Environmental Research and Public Health*, **17**(2), 423 (2020).
52. Wang, Y. Differential effects of sodium selenite and nano-Se on growth performance, tissue Se distribution, and glutathione peroxidase activity of avian broiler. *Biological Trace Element Research*, **128**(2), 184-190 (2009).
53. Naji, K.M., Al-Shaibani, E.S., Alhadi, F.A., Al-Soudi, S.A.A. and D'souza, M.R. Hepatoprotective and antioxidant effects of single clove garlic against CCl4-induced hepatic damage in rabbits. *BMC Complement Altern. Med.*, **17**,411 (2017). <https://doi.org/10.1186/s12906-017-1916-8>.
54. Hassan, F.A., El-Halim, H.A., Sdeek, F.A., Elghalid, O.A. and El-Hady, A.M.A. Protective effects of dietary pomegranate seeds powder supplementation against oxidative stress of organochlorine pesticides residues in growing rabbits. *Adv. Anim. Vet. Sci.*, **9**(8), 1123-1134 (2021). DOI <http://dx.doi.org/10.17582/journal.aavs/2021/9.8.1123.1134>.

55. Rowayshed, G., Salama, A., Abul-Fadl, M., Akila-Hamza, S. and Emad, A. Mohamed. Nutritional and Chemical Evaluation for Pomegranate (*Punica granatum* L.) Fruit Peel and Seeds Powders by Products. *Middle East Journal of Applied Sciences*, **3**(4), 169-179 (2013). ISSN 2077-4613.
56. Behne, D., Alber, D. and Kyriakopoulos, A. Effects of long-term selenium yeast supplementation on selenium status studied in the rat. *J. Trace Elem. Med. Biol.*, **23**, 258–264 (2009). <https://doi.org/10.1016/j.jtemb.2009.05.001>.
57. Bratovic, A. Antioxidant Enzymes and their Role in Preventing Cell Damage. *Acta Sci. Nutr. Health*, **4**, 01–07 (2020). <https://doi.org/10.31080/ASNH.2020.04.0659>.
58. Parashar, A., Ansari, A., Kulshrestra, P. and Gupta, C. Nutritional Effect of Pomegranate Seed Oil in Diet. *Int. J. Biochem. Physiol.*, **3**(1), 000120(2018).
59. Packova, D., Carbonell-Barrachina, A.A. and Kolesarova, A. Ellagitannins--compounds from pomegranate as possible effector in steroidogenesis of rabbit ovaries. *Physiol. Res.*, **64**(4), 583–585 (2015). <https://doi.org/10.33549/physiolres.932971>
60. Procházková, D., Boušová, I. and Wilhelmová, N. Antioxidant and prooxidant properties of flavonoids. *Fitoterapia*, **82** (4), 513–523 (2011). <https://doi.org/10.1016/j.fitote.2011.01.018>.
61. Abdou, M., Magda, I., Abdel-Hamied, N., Mohamady, S. N., Abdullah, S. H. and Gad, G. N. A. The Positive effects of vitamin E and selenium with activated charcoal against aflatoxin induced oxidative stress and cytotoxic damage in rabbits. *Egypt. J. Chem. Environ. Health*, **1**, 798-820 (2015).
62. El-Agamy, D.S. Comparative effects of curcumin and resveratrol on aflatoxin B (1)-induced liver injury in rats. *Arch. Toxicol.*, **84**(5), 389-396 (2010). doi: 10.1007/s00204-010-0511-2. Epub 2010 Jan 30. PMID: 20112103.
63. El-Nekeety, A.A., Abdel-Azeim, S.H., Hassan, A.M., Hassan, N.S., Aly, S.E. and Abdel-Wahhab, M.A. Quercetin inhibits the cytotoxicity and oxidative stress in liver of rats fed aflatoxin-contaminated diet. *Toxicol. Rep.*, **1**, 319-329(2014). doi:10.1016/j.toxrep.2014.05.014.
64. Varior, S. and Philip, B. Aflatoxin B1 induced alterations in the stability of the lysosomal membrane in *Oreochromis mossambicus* (Peters, 1852). *Aquac. Res.*, **43**(8), 1170–1175 (2012). <https://doi.org/10.1111/j.1365-2109.2011.02920.x>.
65. Ali, H., Jahan, A., Samrana, S., Ali, A., Ali, S., Kabir, N., Ali, A., Ullah, R., Mothana, R. A., Murtaza, B. N. and Kalim, M. Hepatoprotective Potential of Pomegranate in Curbing the Incidence of Acute Liver Injury by Alleviating Oxidative Stress and Inflammatory Response. *Frontiers in Pharmacology*, **12**, 694607 (2021). <https://doi.org/10.3389/fphar.2021.694607>.
66. Pfohl, M., DaSilva, N. A., Marques, E., Agudelo, J., Liu, C., Goedken, M., Slitt, A. L., Seeram, N. P. and Ma, H. Hepatoprotective and anti-inflammatory effects of a standardized pomegranate (*Punica granatum*) fruit extract in high fat diet-induced obese C57BL/6 mice. *International Journal of Food Sciences and Nutrition*, **72**(4), 499–510 (2021). <https://doi.org/10.1080/09637486.2020.1849041>

الدور الوقائي لمستخلص بذور الرمان لتقليل سمية الأفلاتوكسين ب 1 في الأرانب

- إهداء أسامه حامد محمد¹ ، حسناء أسامة² ، هويدا علي زهري³ ، سلطان فراج نجاتي⁴ ، وممتاز شاهين⁵
¹ قسم الكيمياء والسموم والنقص الغذائي - وحدة السموم معهد بحوث الصحة الحيوانية (AHRI) - مركز البحوث الزراعية (ARC) - مصر.
² قسم الصيدلة الاكلينيكية - كلية الصيدلة - جامعة بني سويف - مصر.
³ قسم الكيمياء والسموم والنقص الغذائي - وحدة السموم معهد بحوث الصحة الحيوانية (AHRI) - مركز البحوث الزراعية (ARC) - مصر.
⁴ قسم الميكروبيولوجي - معهد بحوث الصحة الحيوانية (AHRI) - مركز البحوث الزراعية (ARC) - مصر.
⁵ قسم الفيروسولوجي - معهد بحوث الصحة الحيوانية (AHRI) - مركز البحوث الزراعية (ARC) - مصر.

هذه الدراسة تهدف إلى تقييم كيفية مواجهة مستخلص بذور الرمان للأثار السلبية لبقايا الأفلاتوكسين ب1 على صحة الكبد ومضادات الأكسدة في الأرانب التي تم تجريعها بسموم الأفلاتوكسين ب1. تم تقسيم عشرون أرنباً عمر ستة أسابيع عشوائياً إلى أربع مجموعات تجريبية. المجموعة الأولى ضابطة سلبية بدون أي معالجة بينما المجموعة الثانية والثالثة تم إعطائها أفلاتوكسين ب1 عن طريق الفم بجرعة 30 ميكرون/كيلو/يوم لمدة 21 يوم وبعد يوم واحد من إعطاء الأفلاتوكسين ب1 تم إعطاء المجموعة الثالثة والرابعة 100 ميلي جرام/كيلو/من مستخلص بذور الرمان. وقد أظهرت النتائج أن الأرانب في المجموعتين الثالثة والرابعة كانت فيها مستويات أنزيمات الكبد والكوليستيرول وثلاثي الجليسريد واللبيروبين الكلي منخفضة والتي كانت عالية في المجموعة الثانية المعالجة بسموم الأفلاتوكسين ب1 مما يشير إلى أن مكملات مستخلص بذور الرمان أدت إلى تحسين وظائف الكبد بالإضافة إلى تقليل مستويات أنزيم المالونالددهيد. وبالمقارنة مع المجموعة الثانية المعالجة بسموم الأفلاتوكسين ب1 كان هناك ارتفاع كبير في نسب أنزيمات السوبر أكسيدديسموتيز والكتاليز والجلوتاثيون بيروكسيديز والجلوتاثيون المختزل. وفقاً للنتائج وجد أن مستخلص بذور الرمان أدى إلى تحسين وظائف الكبد للأرانب المعالجة وحالة مضادات الأكسدة مع القضاء على الأثار الضارة للإجهاد التأكسدي الناتج عن الأفلاتوكسين ب1

الكلمات الدالة: أفلاتوكسين ب 1، مستخلص بذور الرمان ، مضادات الأكسدة، وظائف الكبد ، الأرانب.