



Evaluating the Effect of Topical Flavonoid Luteolin on Skin Wound Healing in Rabbits



Omar T. Mhamed¹, Labeeb H. Al- Alsadoon² and Ghada A. Taqa³

¹Department of Medical Device Technologies Engineering, AL-Hadba University College, Mosul, Iraq dr.omartaha84@hcu.edu.iq

²Mosul Technical Institute, Northern Technical University, Mosul, Iraq labeebhasson@ntu.edu.iq <https://orcid.org/0000-0002-5831-9722>

³Dental Basic Sciences Department, College of Dentistry, University of Mosul, Iraq. ghadataqa@uomosul.edu.iq <https://orcid.org/0000-0001-9683-7881>

BACKGROUND: The aim of this study was to evaluate effect of luteolin nanoparticles cream on wound healing in rabbit skin. **Martial and Methods:** Thirty male rabbits were used in this study. Wound in skin was induced in all rabbits and divided into 5 groups. Group 1: no wound carried out (negative control), Group2: (positive control) dressing wounds by cream only while Groups 3,4,5: dressing wounds by luteolin nanoparticles cream (1%, 2%, 4%), respectively. Treatment was repeated every day. The wound size, tissue type observation assessment were measured at 1st, 3th, 7th days of the experimental procedure. **Results:** At 3th day no significant difference between negative and positive control groups was observed but there are significantly difference between all treated groups of luteolin nanoparticles cream at (1%, 2%, 4%) in comparison to positive control and negative control groups. At day 7 there were significant difference in wounds size between groups treated with luteolin nanoparticles in different concentrations (9.3 ± 1.3 , 7.3 ± 0.6 and 4.0 ± 1.1), respectively and between negative control groups whereas no significant difference within groups treated with luteolin nanoparticles cream in 1%, 2% and 4% (9.3 ± 1.3 , 7.3 ± 0.6 and 4.0 ± 1.1 mm), respectively. Clinical finding of the tissue type that present in the wound showed that epithelization in all groups treated with luteolin nanoparticles in different concentrations in comparison to negative and positive control.

Conclusions: Topical application luteolin nanoparticles cream in different concentrations accelerate skin wounds healing in rabbits.

Keywords: Luteolin, Nanoparticles, Cream, Wound healing, Flavonoid, Rabbits.

Introduction

The wound is described primarily as damage to or disruption of tissue that has led to the loss of its microstructure stability and is undergoing a complex wound healing process [1]. Wound healing is divided into four stages: hemostasis, inflammation, proliferation, and remodeling; each phase must occur in the specified sequence and timeframe for wound healing to be successful [2]. There are three forms of wound healing,

depending on the time and method of closure: healing by primary intention, secondary intention, and tertiary intention. Healing by primary intention involves the surgical apposition of the wound margins, commonly with sutures. When surgical closure is not feasible, wounds heal through secondary intention. With secondary intention healing, wounds must heal from the bottom up, which can be slow and result in scar development [3, 4]. Healing by tertiary intention, when surgical wounds are left exposed to heal by

secondary intention, until any abscesses infection or when dehiscence or contaminated-dirty wounds occur [5].

Luteolin nanoparticles (3,4,5,7-tetrahydroxy flavone) is a natural dietary flavonoid, commonly present at high concentrations in several types of fruits, vegetables, and medicinal herbs [6]. Luteolin nanoparticles was initially discovered in 1829 by Michel Eugène Chevreul, a French chemist who extracted luteolin nanoparticles in its pure state [7]. Structurally, the presence of hydroxyl moieties at carbons 5, 7, 3, and 4 positions of the luteolin nanoparticles structure and the presence of the 2 - 3 double bonds usually have different pharmacological benefits or effects [8]. A clinical epidemiology study demonstrates that luteolin nanoparticles has various biological and pharmacological activities, such as antioxidation activity, anti-inflammatory effect, antiviral action, antibacterial action, hypoglycemic effect, antitumor activity, hypolipidemic effect, immunomodulatory functions, hypotensive effect, etc. [9].

The primary goal of wound management is to restore tissue anatomical continuity, which is required to avoid infections from the external environment and preserve internal environment homeostasis [10]. Some medications are used to accelerate the healing of wounds, therefore we use luteolin nanoparticles because it has antioxidant and anti-inflammatory action, and can be used to investigate the systemic effects on wound healing [11]. Thus, this study aimed to evaluate the effect of different concentrations of luteolin nanoparticles cream topically applied on skin wound healing in rabbits .

Material and Methods

Luteolin nanoparticles cream preparation

Luteolin nanoparticles cream were prepared in three different concentrations (1%, 2%, 4%) by mixing (1, 2, 4 g) from Luteolin nanoparticles pure powder purchased from (Yanhuang Industrial Park, Guanxian, Liaocheng, Shandong, China). in 100 g cream to give final concentration (1%, 2%, 4%) W/W .

Animals

In the present study, we selected thirty healthy male local rabbits aged between (10-12) month, about 1.5-2.0 kg weighted. Rabbits were obtained from animal housed in College of Veterinary Medicine, Mosul University, Iraq. Dorsal area

of all rabbits were shaved to remove hair and prepared for surgery and covered with sterile towel exposing dorsal side only. All animals were anesthetized by mixture of ketamine and xylazine (40+5) mg/kg i.m, respectively [12]. Five minutes after anesthesia injection, the rabbits reflexes were checked to ensure that anesthesia were taken. Each animal was anesthetized, laid down in ventral side on the surgical board. On each animal, created four longitudinal full thickness incision (10 mm) on the dorsal of rabbits. After induced the wound on skin, Animals were divided into 5 groups/ 6 rabbits for each group and treated (daily dressing wound) locally as the following:

Group 1: no treatment skin (negative control)

Group 2: treatment skin wound by cream only (positive control)

Group 3: Treated skin wound by Luteolin nanoparticles cream 1%

Group 4: Treated skin wound by Luteolin nanoparticles cream 2%

Group 5: Treated skin wound by Luteolin nanoparticles cream 4%

Dressing treatment were repeated every day, and the wound size (length and width) and observation of the tissue type (Score) were measured in 1st, 3th, 7th days of the experiment [13, 14].

Statistical analysis:

The results were reported as mean \pm SD, and the statistical difference between the experimental groups was assessed using a one-way ANOVA test. Duncan's Multiple Range Test was then used to show any parametric significance associations. The p-value ≤ 0.05 significance level was used.

Results

In the this study at first day it was found that no significant difference in wound size in negative and positive control group and all treated groups with Luteolin nanoparticles cream (Table 1 & Fig. 1).

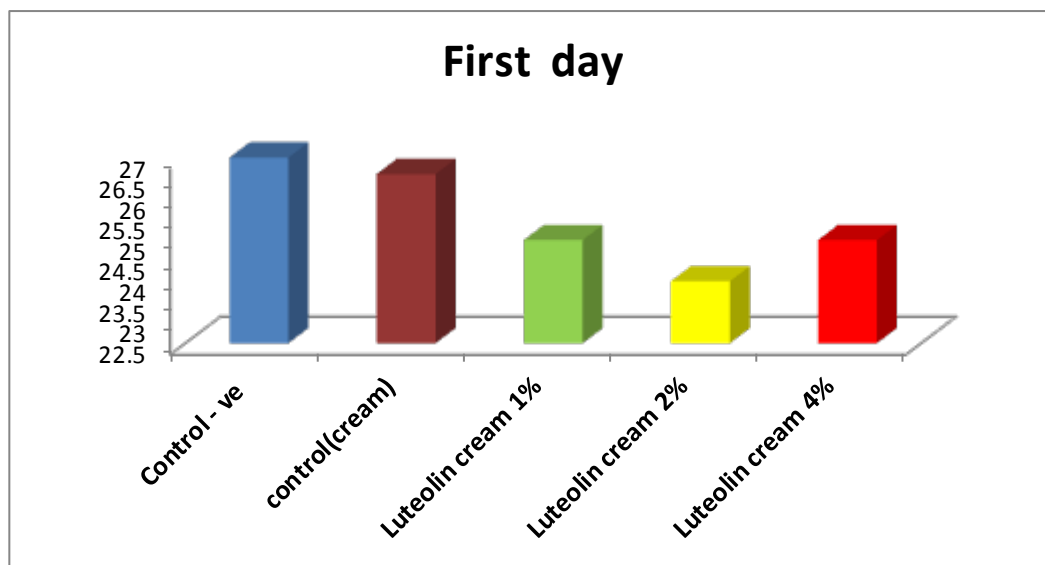
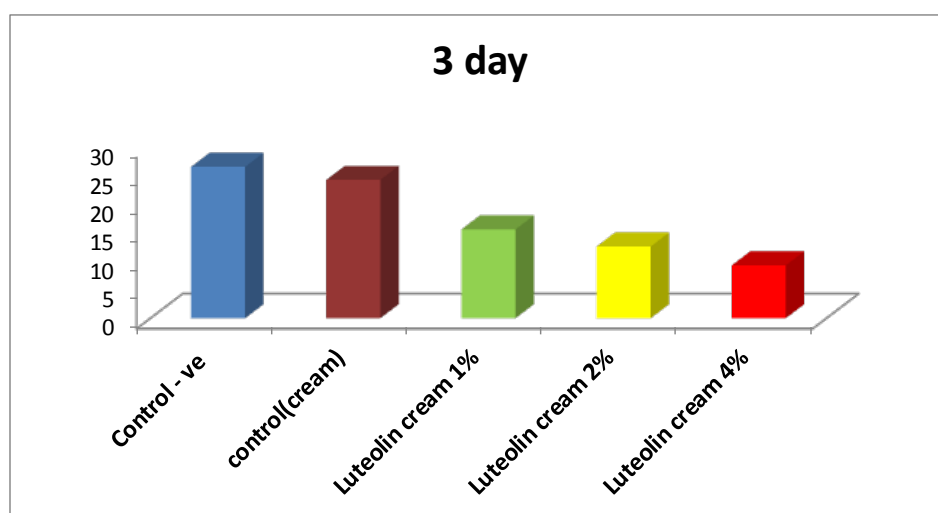
At 3 day no significant differences between negative and positive control groups (Fig. 2) was recorded but there are significantly differences between all treated groups of Luteolin nanoparticles cream at (1%, 2%, 4% concentration) in comparison with control positive and control negative groups (Fig. 2) .

TABLE 1. Effect of Luteolin nanoparticles cream (1%, 2%,4% Topically) on skin wound healing (mm²).

| Groups | Day 1 | Day 3 | Day 7 |
|---------------------------------|------------------------|------------------------|------------------------|
| Negative control | 27 ± 0.0 ^{aA} | 26.6±2.6 ^{aA} | 17±2.6 ^{aB} |
| Control (cream only) | 26.6±4.6 ^{aA} | 24.3±3.5 ^{aA} | 14.3±0.0 ^{bB} |
| 1% Luteolin nanoparticles cream | 25.0±1.7 ^{aA} | 15.6±2.3 ^{bB} | 9.3±1.3 ^{bC} |
| 2% Luteolin nanoparticles cream | 24.0±0.0 ^{aA} | 12.6±2.3 ^{bB} | 7.3±0. 6 ^{cC} |
| 4% Luteolin nanoparticles cream | 25.0±1.7 ^{aA} | 9.3 ±1.3 ^{bB} | 4.0± 1.1 ^{cC} |

-Capital letters indicate significant differences at p-value ≤ 0.05 in the same raw data.

-In the same Column, various small letters indicate significant differences with p-value ≤ 0.05.

**Fig. 1.** Effect of Luteolin nanoparticles cream(1%,2%,4%) at First day**Fig. 2.** Effect of Luteolin nanoparticles cream(1%,2%,4%) at 3 days

There were significant differences between groups treated with luteolin nanoparticles in different concentrations (9.3 ± 1.3 , 7.3 ± 0.6 & 4.0 ± 1.1 , respectively) and between negative control group but no significant difference between positive control group (14.3 ± 0.0) and 1% Luteolin nanoparticles cream (9.3 ± 1.3). whereas no significant difference within groups treated by Luteolin nanoparticles cream in 1%, 2% and 4% (9.3 ± 1.3 , 7.3 ± 0.6 and 4.0 ± 1.1), respectively (Fig. 3).

Within negative control group no significantly differences after 3 days (26.6 ± 2.6) in comparison to first day (27 ± 0.0) but significant differences

after 7 days (17 ± 2.6) in comparison to first day (27 ± 0.0) was recorded (Fig. 4).

Within positive control group no significantly differences were observed after 3 days (24.3 ± 3.5) in comparison to first day (26.6 ± 4.6) but significantly difference after 7 days (14.3 ± 0.0) of treatment in comparison to first day (26.6 ± 4.6), (Fig. 5).

Within luteolin nanoparticles cream 1% group there are a significant differences after 7 days (9.3 ± 1.3) in comparison to first and 3rd days (25.0 ± 1.7) (15.6 ± 2.3), respectively. Also there were significant variation after 3 days (15.6 ± 2.3) in comparison to first day (25.0 ± 1.7), Fig. 6.

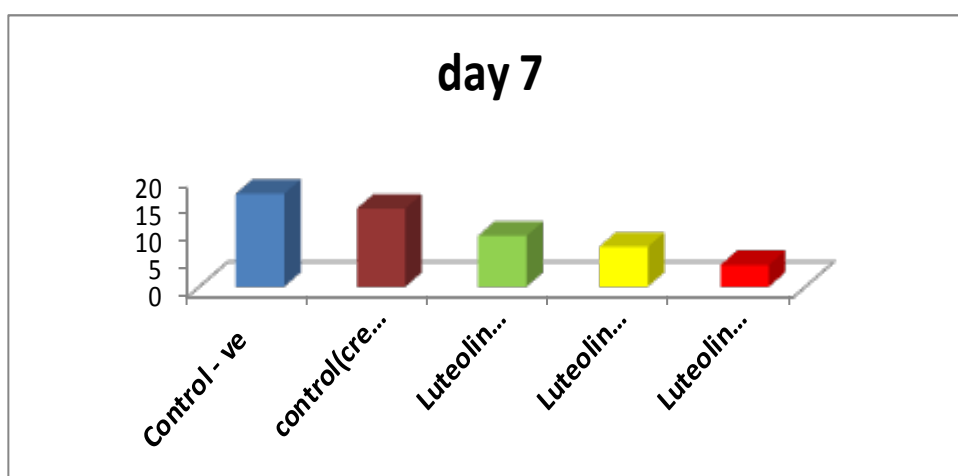


Fig. 3. Effect of Luteolin nanoparticles cream (1%, 2%, 4%) at 7 day

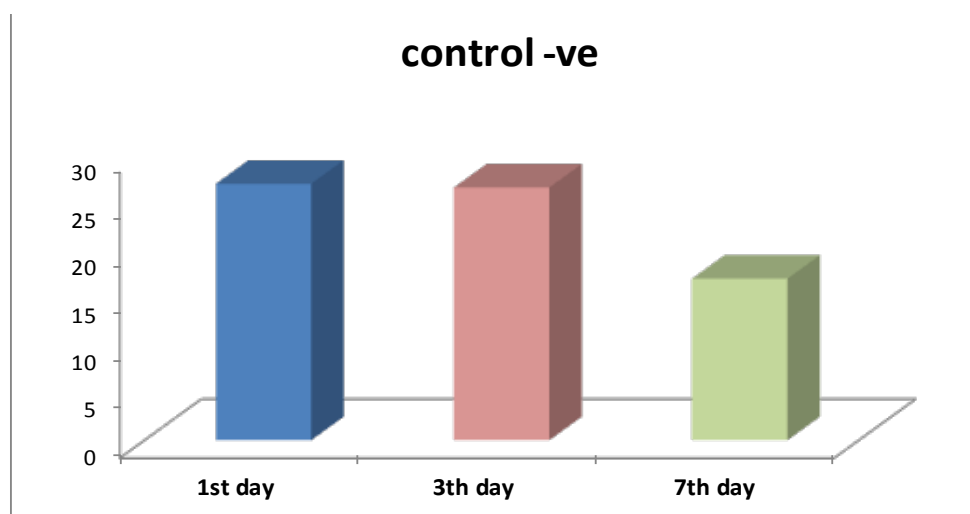


Fig. 4. Size of wound in control group in different time period

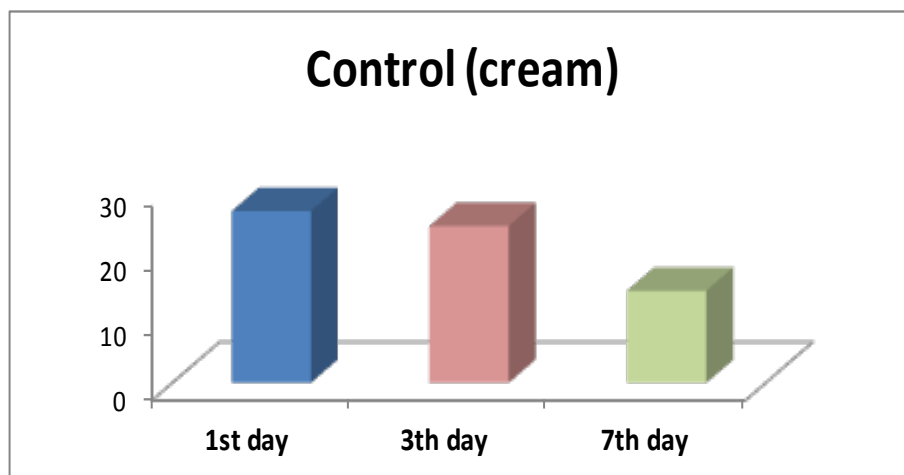


Fig. 5. Size of wound in control positive in different time period

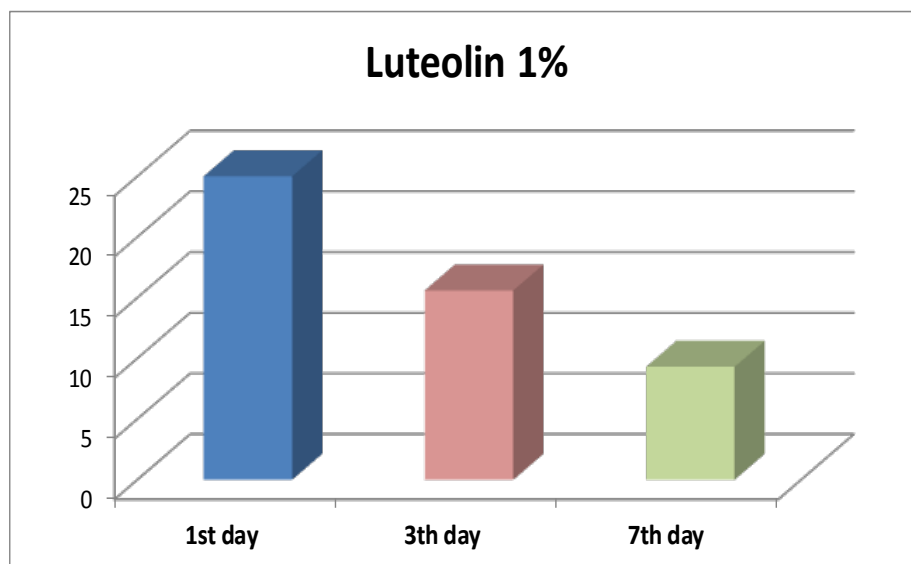


Fig. 6. Size of wound healing in luteolin nanoparticles 1% topically treated in different time period.

In luteolin nanoparticles cream 2% group, there are a significant differences after 7 days (7.3 ± 0.6) in comparison to first and 3rd days (24.0 ± 0.0 , 12.6 ± 2.3 , respectively). Also there are a significant difference after 3 days (12.6 ± 2.3) in comparison to first day (24.0 ± 0.0), Fig. 7.

In **Luteolin nanoparticles** cream 4% group, there are a significant differences after 7 days (4.0 ± 1.1) in comparison to first and 3rd days (25.0 ± 1.7 , 9.3 ± 1.3 respectively). Also there were significant differences after 3 days (9.3 ± 1.3) in comparison to first day (25.0 ± 1.7), Fig. 8.

Observation of the tissue type that were present in the wound: The results revealed that the score of group treated with luteolin nanoparticles in different concentrations are declined after first day of treatment from necrotic tissue to slough (Table 2). Wound healing were converting to granulation tissue in group treated with luteolin nanoparticles in different concentrations that declined after 3 days in comparison with negative control (slough) and positive control (slough), Fig. 9.

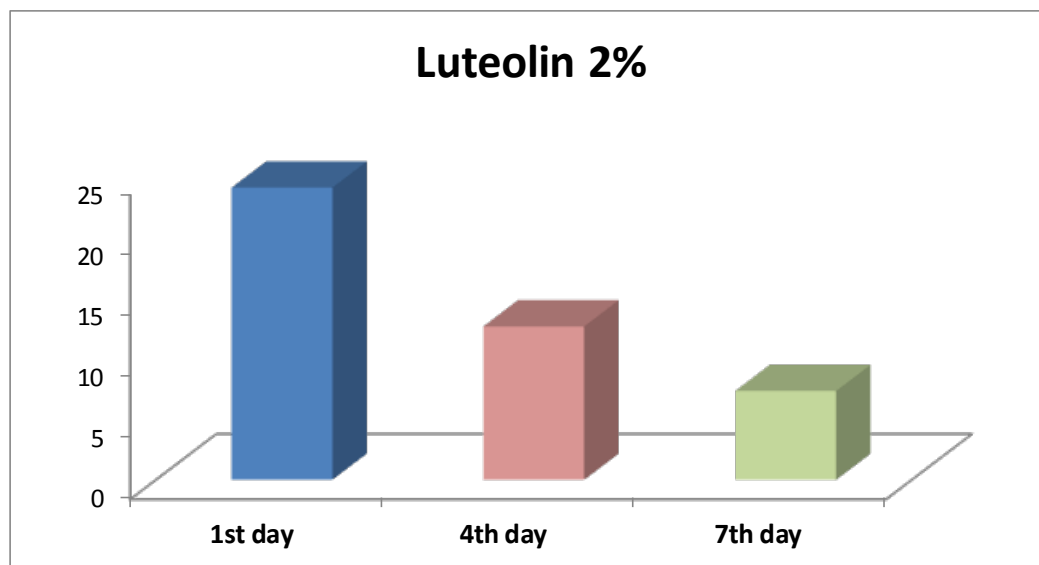


Fig. 7. Size of wound healing in Apigenin 2% topically treated in different time period

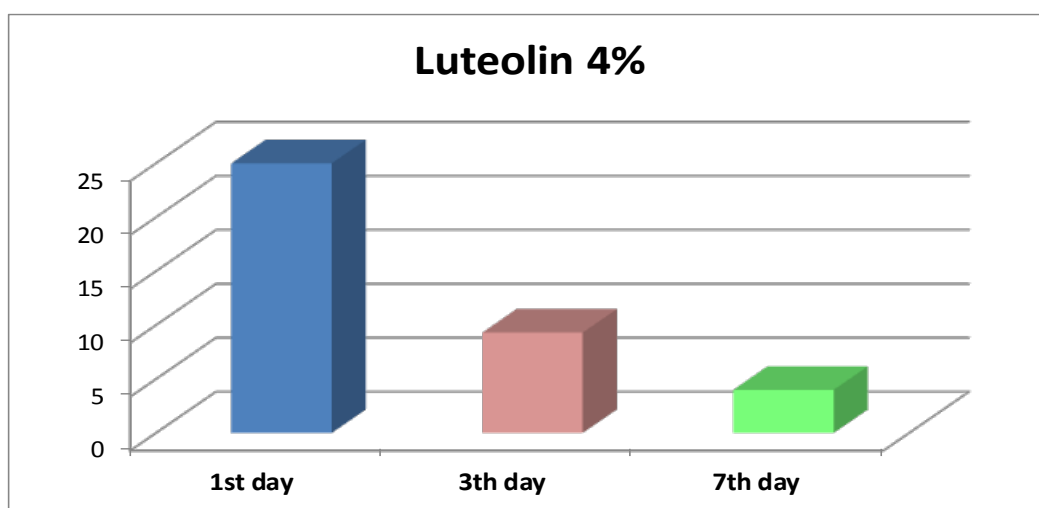


Fig. 8. Size of wound healing in Luteolin nanoparticles 4% topically treated in different time period

TABLE 2. Tissue type score after Luteolin nanoparticles cream (1%, 2%, 4% Topically) applied on skin wound healing.

| Groups | Day 1 | Day 3 | Day 7 |
|---------------------------------|-------------------------|------------------------|------------------------|
| Control – ve | 4.0 ± 0.0 ^{aA} | 3.3±0.3 ^{aB} | 3.0±0.0 ^{aB} |
| Control (cream) | 4.0 ±0.0 ^{aA} | 3.0±0.0 ^{aB} | 2.6±0.3 ^{aB} |
| 1% Luteolin nanoparticles cream | 3.33±0.3 ^{bA} | 2.3±0.3 ^{bAB} | 1.6±0.3 ^{bB} |
| 2% Luteolin nanoparticles cream | 3.0±0.0 ^{bA} | 2.0±0.0 ^{bB} | 1.3±0.3 ^{bC} |
| 4% Luteolin nanoparticles cream | 3.0±0.0 ^{bA} | 2.0 ±0.0 ^{bB} | 1.0± 0.0 ^{bC} |

At day 7 tissue observation were epithelization in all groups treated with luteolin nanoparticles in different concentrations. In negative control and positive control types of tissue formation convert from necrotic tissue to slough tissue. While in luteolin nanoparticles in different concentration groups the types of tissue formation started from necrotic tissue, slough, granulation tissue and epithelial tissue at 7th days. (Fig. 9).

Discussion

Nowadays, a variety of medications are used to quicken wound healing. However, the medications used to repair wounds have some flaws and negative effects. Despite all efforts to speed up wound healing, no safe medication has yet been developed for this use. Consequently, it is crucial to recognize herbal plants that have healing properties [15].

One of the most potent flavonoids has been found to be luteolin nanoparticles, which is extensively distributed in a variety of foods, plants, and herbs. Numerous biological functions and therapeutic effects of luteolin nanoparticles have been discovered, including antioxidant, anti-inflammatory, and the ability to overcome resistance to anti-neoplastic drugs [16].

Although reactive oxygen species (ROS) can serve in the regulation of repair, excessive development of ROS, on the other hand, impairs healing. ROS is generated in wounds by leukocytes migrating to the wound, as well as injured epithelial cells, which produce a hydrogen peroxide (H₂O₂) gradient in the injured tissue's margins. Migrating leukocytes are attracted to the

healing environment by this gradient [17]. ROS are required for the phagocytosis of microorganisms and they stimulate the cytokine cascade by activation of nuclear factor- κ B (NF- κ B) [18]. Hydrogen peroxide affects reepithelialization, induces collagen type (I, III, and IV) synthesis, and affects the conversion of fibroblasts to myofibroblasts [19]. Excessive oxidative stress, on the other hand, has a negative effect on wound healing; it induces senescence of fibroblast and impairs contraction. The pathophysiology of numerous types of injury in tissue damage and organ dysfunction depends on the production of large levels of reactive oxygen species (ROS) during reperfusion and the activation of significant epithelial apoptosis [20]. However, there has been evidence of a positive effect of antioxidant intervention in wound healing [21]. In order to facilitate wound healing, oxidative stress-induced damage may be reduced by lowering ROS levels through antioxidative mechanisms [22].

According to the results of the current study, animals who received luteolin nanoparticles treatment shown potential benefits for improving wound healing, presumably as a result of the plant's capacity to scavenge free radicals [23]. Compared to vitamin E, luteolin nanoparticles has two times the antioxidant capacity and possesses powerful superoxide radical scavenging abilities [24].

In agreement with current findings, experiments on animals have shown that luteolin nanoparticles possesses antioxidant and anti-inflammatory properties [25]. Also, Luteolin nanoparticles acts in several ways, including direct quenching

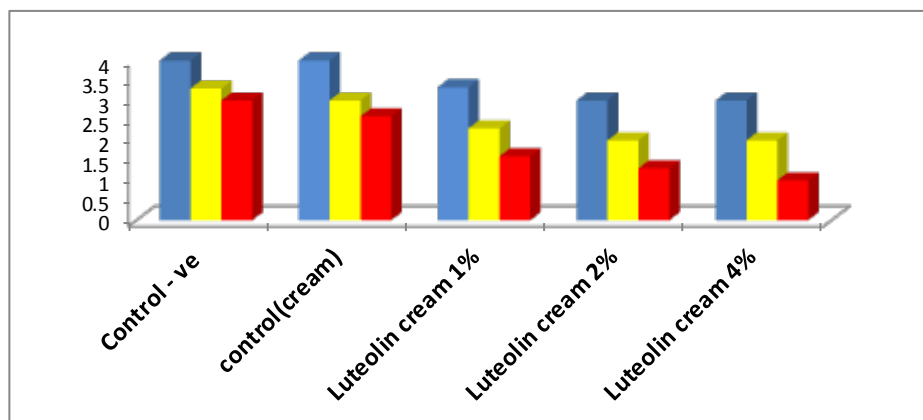


Fig. 9. Tissue type score after Luteolin nanoparticles cream (1%, 2%, 4% Topically) applied on skin wound healing in different period times

of reactive oxygen species, chelation of metal ions (Fe^{3+} , Cu^{+}), and regeneration of membrane-bound antioxidants such as R-tocopherol [26].

The ability of luteolin nanoparticles to scavenge reactive oxygen and nitrogen species, bind transition metals that may cause oxidative damage through the Fenton reaction, block pro-oxidant enzymes, and activate antioxidant enzymes has been linked to its antioxidant activity [27]. Also luteolin nanoparticles enhances endogenous antioxidants such as catalase (CAT), superoxide dismutase (SOD), glutathione-S-transferase (GST), and glutathione reductase (GR) [28]. Furthermore, luteolin nanoparticles decrease inhibit the lipid peroxidation which will decrease MDA levels [29].

The present study revealed a decrease in wound size and accelerate closed wound this may be return to eliminate of reactive oxygen species and decrease in oxidative stress in all luteolin nanoparticles treated groups and which in turn would accelerate the wound healing process of the skin. This is in line with [30] that show that the generation of reactive oxygen species delayed blood clotting, prolonged inflammation, bacterial infection, and slower cell proliferation which are the main challenges to effective wound repair.

Hemostasis, inflammation, proliferation, and remodeling are only a few of the biological processes that interact and overlap during the complicated and sequential biological process of wound healing. Any issue with these procedures will result in persistent wounds or even wounds that never heal [20].

Our study showed that the inflammatory response is decreased, this is in agreement with Aziz, 2018 that luteolin nanoparticles has been shown to have an anti-inflammatory effect in vitro, in vivo, and in clinical studies strongly hints that this activity derives from luteolin nanoparticles regulation of transcription factors like STAT3, nuclear factor kappa-light-chain-enhancer of activated B cells (NF- κ B), and Activator protein 1 (AP-1) [8]. Luteolin nanoparticles was the most potent inhibitor of ROS generation. And inhibited NO production and iNOS protein expression in LPS-stimulated macrophages [31]. The scavenging of reactive oxygen species (ROS), inhibition of ROS production and activation of antioxidant enzymes, inhibition of leukotriene production and release, suppression of pro-inflammatory cytokine expression, inhibition

of the NF- κ B pathway, protein kinase B (AKT), and mitogen-activated protein kinase (MAPK) have all been linked to luteolin nanoparticle's anti-inflammatory effects. Besides the capacity to scavenge hydrogen peroxide and reducing prostaglandin E2, tumor necrosis factor (TNF) as well as the expression of cyclooxygenase-2 [32].

Conclusion

The result findings of the present research showed accelerated healing of the wounds in groups treated with luteolin nanoparticles and accelerate closed wound as well as wound were converting to granulation tissue in group treated with luteolin nanoparticles in different concentration after 3 day.

Acknowledgement

Great thanks to the College of Dentistry, University of Mosul, Department of Dental Basic Sciences for their support to conduct this study.

Conflicts of interest

The authors declared no competing interests.

Funding/Support

None.

References

1. Salleh, A. and Fauzi, M. B. The In Vivo, In Vitro and In Ovo Evaluation of Quantum Dots in Wound Healing: A Review. *Polymers*, **13**(2), 191(2021).
2. Shah, R., Domah, F., Shah, N. and Domah, J. Surgical Wound Healing in the Oral Cavity: a Review. *Dental Update*, **47**(2), 135-143. (2020).
3. Pun, S. H. Reining in the Wound-Healing Response in an Equine Model with a Biomimetic Hydrogel. *American Chemical Society*, **7**(1), 1-382 (2021).
4. Mohammed, S. M., Sulaiman, M. S. and Taqa, G. A. Effects of Melatonin on Primary Oral Wound Healing in Rats. *Journal of Applied Veterinary Sciences*, **7**(1), 24-30 (2022).
5. Foghetti, D. Infection in Surgery: How to Manage the Surgical Wound. In *Infections in Surgery*, 37-50(2021).
6. Radziejewska, I., Borzym-Kluczyk, M. and Leszczyńska, K. Luteolin nanoparticles alters MUC1 extracellular domain, sT antigen, ADAM-17, IL-8, IL-10 and NF- κ B expression in *Helicobacter pylori*-infected gastric cancer CRL-1739 cells: A preliminary study. *Biomedical Reports*, **14**(2), 1-1(2021).

7. Jain, R. and Tiwari, A. Monograph: Luteolin nanoparticles . *Matrix Science Medica*, **4**(3), 88-88. (2020).
8. Aziz, N., Kim, M. Y. and Cho, J. Y. Anti-inflammatory effects of luteolin nanoparticles : A review of in vitro, in vivo, and in silico studies. *Journal of Ethnopharmacology*, **225**, 342-358(2018).
9. Wu, C., Xu, Q., Chen, X. and Liu, J. Delivery luteolin nanoparticles with folacin-modified nanoparticle for glioma therapy. *International Journal of Nanomedicine*, **14**, 7515(2019).
10. Jeong, S. H., Lee, Y., Lee, M. G., Song, W. J., Park, J. U. and Sun, J. Y. Accelerated wound healing with an ionic patch assisted by a triboelectric nanogenerator. *Nano Energy*, **79**, 105463(2021).
11. Ghaderi, R., Afshar, M., Akhbarie, H., Golalipour, M. J., Ghaderi, R. and Afshar, M. Comparison of the efficacy of honey and animal oil in accelerating healing of full thickness wound of mice skin. *Int. J. Morphol.*, **28**(1), 193-198(2010)..
12. Taqa, G. A. and Albanna, S. S. Histological and Clinical Finding of Systemic Melatonin on Wound Healing after Tooth Extraction in Rabbits. *Journal of Applied Veterinary Sciences*, **7**(1), 18-23 (2022).
13. Taqa, G.A., Mustafa, E. A. and Al-Haliem, S.M. Evaluation of Anti-Bacterial and Efficacy of plant extract (*Urtica urens*) on Skin Wound Healing in Rabbit. *International Journal of Enhanced Research in Science Technology and Engineering*, 64-70(2014).
14. Al-Jureisy, I.T, Al-Wattar, W.T. and Taqa, Gh. A. The Topical Effect of Coenzyme Q10 on Wound Healing in Mice. *Al-Rafidain Dent. J.*, **19** (1), 42-51(2019).
15. Solati, K., Karimi, M., Rafieian-Kopaei, M., Abbasi, N., Abbaszadeh, S. and Bahmani, M. Phytotherapy for wound healing: The most important herbal plants in wound healing based on iranian ethnobotanical documents. *Mini Reviews in Medicinal Chemistry*, **21**(4), 500-519(2021).
16. Huang, X., Bhugul, P. A., Fan, G., Ye, T., Huang, S., Dai, S. and Zhou, M. Luteolin nanoparticles inhibits pancreatitis-induced acinar-ductal metaplasia, proliferation and epithelial-mesenchymal transition of acinar cells. *Molecular Medicine Reports*, **17**(3), 3681-3689(2018).
17. Niethammer, P., Grabher, C., Look, A. T. and Mitchison, T. J. A tissue-scale gradient of hydrogen peroxide mediates rapid wound detection in zebra fish. *Nature*, **459**(7249), 996-999(2009).
18. Hensley, K., Robinson, K. A., Gabbita, S. P., Salsman, S. and Floyd, R. A. Reactive oxygen species, cell signaling, and cell injury. *Free Radical Biology and Medicine*, **28**(10), 1456-1462(2000).
19. Sen, C. K. The general case for redox control of wound repair. *Wound Repair and Regeneration*, **11**(6), 431-438(2003).
20. Chen, Y., Liang, Y., Liu, J., Yang, J., Jia, N., Zhu, C. and Zhang, J. Optimizing microenvironment by integrating negative pressure and exogenous electric fields via a flexible porous conductive dressing to accelerate wound healing. *Biomaterials Science*, **9**(1), 238-251(2021).
21. Soneja, A., Drews, M. and Malinski, T. Role of nitric oxide, nitroxidative and oxidative stress in wound healing. *Pharmacological Reports*, **57**, 108-119(2005).
22. Deng, L., Du, C., Song, P., Chen, T., Rui, S., Armstrong, D. G. and Deng, W. The role of oxidative stress and antioxidants in diabetic wound healing. *Oxidative Medicine and Cellular Longevity*, eCollection, 8852759(2021). doi: 10.1155/2021/8852759.
23. Lodhi, S. and Singhai, A. K. Wound healing effect of flavonoid rich fraction and luteolin nanoparticles isolated from *Martynia annua* Linn. on streptozotocin induced diabetic rats. *Asian Pacific Journal of Tropical Medicine*, **6**(4), 253-259 (2013).
24. Del Bano, M. J., Castillo, J., Benavente-García, O., Lorente, J., Martín-Gil, R., Acevedo, C. and Alcaraz, M. Radioprotective– antimutagenic effects of rosemary phenolics against chromosomal damage induced in human lymphocytes by γ -rays. *Journal of Agricultural and Food Chemistry*, **54**(6), 2064-2068(2006).
25. Al-Megrin, W. A., Alkhuriji, A. F., Yousef, A. O. S., Metwally, D. M., Habotta, O. A., Kassab, R. B. and El-Khadragy, M. F. Antagonistic efficacy of luteolin against lead acetate exposure-associated with hepatotoxicity is mediated via antioxidant, anti-inflammatory, and anti-apoptotic activities. *Antioxidants*, **9**(1), 10 (2020).

-
26. Leopoldini, M., Pitarch, I. P., Russo, N. and Toscano, M. Structure, conformation, and electronic properties of apigenin, luteolin nanoparticles, and taxifolin antioxidants. A first principle theoretical study. *The Journal of Physical Chemistry A*, **108**(1), 92-96(2004).
 27. Juan-Badaturuge, M., Habtemariam, S., Jackson, C. and Thomas, M.J. Antioxidant principles of *Tanacetum vulgare* L. aerial parts. *Natural Product Communications*, **4**(11), 1934578X0900401121(2009).
 28. Asiri, A. Therapeutic Effect of Luteolin nanoparticles in Diabetic Wounds: Minireview. *European Journal of Molecular & Clinical Medicine*, **7**(3), 692-698 (2020).
 29. Alshehri, S., Imam, S.S., Altamimi, M. A., Jafar, M., Hassan, M. Z., Hussain, A. and Mahdi, W. Host-guest complex of β -cyclodextrin and pluronic F127 with Luteolin nanoparticles : Physicochemical characterization, anti-oxidant activity and molecular modeling studies. *Journal of Drug Delivery Science and Technology*, **55**, 101356 (2020).
 30. Ahmadian, Z., Correia, A., Hasany, M., Figueiredo, P., Dobakhti, F., Eskandari, M. R. and Shahbazi, M. A. A Hydrogen-Bonded Extracellular Matrix-Mimicking Bactericidal Hydrogel with Radical Scavenging and Hemostatic Function for pH-Responsive Wound Healing Acceleration. *Advanced Healthcare Materials*, **10**(3), 2001122 (2021).
 31. Choi, J. S., Islam, M. N., Ali, M. Y., Kim, Y. M., Park, H. J., Sohn, H. S. and Jung, H. A. The effects of C-glycosylation of luteolin nanoparticles on its antioxidant, anti-Alzheimer's disease, anti-diabetic, and anti-inflammatory activities. *Archives of Pharmacol. Research*, **37**(10), 1354-1363 (2014).
 32. Gendrisch, F., Esser, P. R., Schempp, C. M. and Wölflle, U. Luteolin nanoparticles as a modulator of skin aging and inflammation. *BioFactors*, **47**(2), 170-180 (2021).

تقييم التأثير الموضعي للوتولين الفلافونويد على التئام جروح الجلد في الأرانب

^١عمر طه محميد و ^٢ليب حسون عبد الله و ^٣غادة عبد الرحمن طاقة .

^١ قسم هندسة تقنيات الأجهزة الطبية، كلية الحداثة الجامعة ، الموصل ، العراق

^٢ المعهد التقني الموصل ، الجامعة التقنية الشمالية ، الموصل ، العراق

^٣ قسم علوم طب الاسنان الاساسية ، كلية طب الأسنان ، جامعة الموصل ، الموصل ، العراق

تقييم التأثير الموضعي للوتولين الفلافونويد على التئام جروح الجلد في الأرانب

الخلفية: الهدف من هذه الدراسة هو تقييم تأثير كريم اللوتولين النانوي على التئام الجروح في جلد الأرانب. **المواد وطرائق العمل:** استخدام ثلاثين ذكرًا من الأرانب في هذه الدراسة. تم عمل الجروح في الجلد في جميع الأرانب وقسمت بعد ذلك إلى ٥ مجموعات. المجموعة ١: لا يوجد علاج للجروح (تحكم سلبي) ، المجموعة ٢: (تحكم إيجابي) تضميد الجرح بالكريم لوحده بينما المجموعة ٣، ٤، ٥: تضميد الجروح بكريم الجسيمات النانوية لوتولين بتركيز (١٪ ، ٢٪ ، ٤٪) على التوالي. وتم تكرار العلاج كل يوم. وتم قياس حجم الجروح وملاحظة نوع الأنسجة في اليوم الأول والثالث والسابع من التجربة. **النتائج:** في اليوم الثالث لم يكن هناك فرقًا معنويًا بين مجموعة التحكم السلبي ومجموعة التحكم الإيجابي ولكن كان هناك فرق معنوي بين جميع المجموعات المعالجة من كريم الجسيمات النانوية اللوتولين عند (١٪ ، ٢٪ ، ٤٪) مقارنة بمجموعة السيطرة الإيجابية والسلبية. في اليوم السابع كان هناك فرق معنوي في حجم الجرح بين المجموعات المعالجة بجسيمات لوتولين النانوية بتركيز مختلفة (١،٣ ± ٩،٣) (٠،٦ ± ٧،٣) (١،١ ± ٤،٠) على التوالي وبين المجموعات الضابطة بينما لم يكن هناك فرق معنوي داخل المجموعات المعالجة بكريم الجسيمات النانوية اللوتولين في ١٪ و ٢٪ و ٤٪ (٩،٣ ± ١،٣) (٠،٦ ± ٧،٣) و (١،١ ± ٤،٠) ملم على التوالي. الاستنتاجات أظهرت النتائج السريرية ان الاستخدام الموضعي لكريم اللوتولين بتركيز مختلفة قد عمل على الاسراع من شفاء جروح الجلد في الارانب

الكلمات المفتاحية: اللوتولين ، الجزيئات النانوية ، كريم ، شفاء الجروح ، الفلافونويد .