



Study the Thorax Ossification Centers in Partridge Embryos by Alizarin Red and Alcian Blue Double Staining Techniques



Masoud Sahimirad¹, Hassan Gilanpour¹, Mohammadreza Paryani^{2*}, Bijan Radmehr³ and Abbas Veshkini⁴

¹Department of Basic Sciences and Hygiene, Science and Research Branch, Islamic Azad University, Tehran, Iran.

²Department of Basic Sciences, Karaj Branch, Islamic Azad university, Karaj, Iran.

³Department of Basic Sciences, Faculty of Veterinary Medicine, University of Tehran, Tehran, Iran.

⁴Department of Clinical Sciences, Science and Research Branch, Islamic Azad University, Tehran, Iran.

THE current study was aimed to determine the onset of vertebral ossification, ribs, and sternum, and to evaluate ossification centers using the alizarin red and alcian blue staining techniques in the partridge embryos. One-hundred fertilized eggs of the partridge were placed in a hatching machine. From day 8 of incubation, three egg samples were randomly selected daily for staining until hatching. After staining, ossification centers in various parts of thorax were evaluated by a stereomicroscope. Data from examination of different thoracic parts of the partridge embryos indicated that cartilaginous thoracic vertebrae were formed in the embryo on the 8th day, but the ribs and sternum were not visible. Cartilaginous ribs were formed on the 9th day of embryo. A cartilaginous sternum began to form on the 10th day of embryo. On the 13th day, cartilaginous unciniate processes were observed at the caudal border of embryonic ribs. From the 16th day, the first ossification center was detected in the body of ribs. The embryonic development process was progressive on the 17th and 18th days. The first ossification centers in the embryo of the 22nd and 23rd days were detectable in the cranio-lateral process of sternum and in the unciniate process of the first thoracic rib, respectively. On the 25th day, the cranio-medial process of sternum was the first ossification center in the embryos. The emergence of ossification centers in different parts of thorax and the developmental process were not observed at the pre-hatching time.

Keywords: Ossification centers, Thorax, Partridge embryo, Alizarin red, Alcian blue.

Introduction

Anatomical-, embryological-, and histological-based researches on the embryonic and adult skeletal systems of body parts have been of great importance [1]. Abundant researches were conducted on broiler chick, quail, turkey, and duck with special aspects of leg skeletal development, vertebral column, and knee joint [2-6] or evolutionary development of a particular bone, such as tibiotarsus or tarsometatarsus [7], which only occasional focus on other parts of the skeleton.

Chukar partridge (*Alectoris chukar*) is a medium-size partridge and considered as one of the most eminent species of this genus mainly used for breeding. The bird weighs 600 g on average and lays about 40-50 eggs during the reproduction season. It is well-adapted with hard breeding conditions and have a rapid growth [8]. The flesh of partridge possesses unique nutritional potentials, including higher protein, lower cholesterol, and faster digestion than other animal proteins and even chicken, making it a good source of animal protein, particularly in the elderly and children.

[9]. Thus, it is essential to study the skeletal and anatomical properties of chukar partridge as a good sources of nutritive eggs and neat.

Existing evidence indicate that histological and anatomical studies have been conducted on different organs of partridge, including wing skeleton [10], leg skeleton [11], thymus [12], spleen [12], liver [13], esophagus [14], knee joint [15], and so on by various researchers. Respiration is very important in birds, in particular flying birds with high metabolism that spend high energy to fly, and thorax also plays an important role in the process of respiration. However, there were no available studies on the skeleton and ossification process of thorax in partridge. Thus, the present study was carried out to examine thoracic ossification centers and the time, formation, and completion of bones in chukar partridge.

Materials and Methods

Ethics

The study was ethically approved by the Faculty of Veterinary Medicine, Science and Research Branch, Islamic Azad University, Tehran, Iran (Ethical Approval Number IR.IAU.SRB.REC.1396.153).

Partridge eggs

In this study, 100 fertilized eggs of chukar partridge (*Alectoris chukar*) were obtained from a partridge-breeding farm. Eggs were confirmed by an expert professor of the field of poultry breeding. The eggs were incubated in a hatching machine (Jamesway 252B incubators, Wall Incubator, Carlyle, Illinois, USA) at 37-38 °C with a humidity of 55-56% according to the instructions of the manufacturer. Hatching machine was disinfected with formalin gas.

Inclusion and exclusion criteria

All fertilized eggs of chukar partridge contained healthy embryo were included in this experiment. Eggs contained dead embryos, problems such as bone and joint fractures and mortality are considered as exclusion criteria of the experiment.

Embryonic experiment

On days 7 and 14 of incubation, fertile eggs were examined using a special egg Candler. From day 8 of incubation, three egg samples were randomly selected daily until hatching. To access the embryo, the calcified eggshells were removed from the air chamber, embryonic membranes were separated, and the embryos were placed in

76% ethanol solution (Merck, Germany). These stages were repeated every day until hatching and samples were kept in the fixative.

Staining protocol

The samples were stained using the alizarin red and alcian blue staining techniques[-]. Samples (7 days old embryos) were fixed and stained for 2 days at 37°C in a freshly prepared solution of ethanol (95%, 80 mL), glacial acetic acid (20 mL, Merck, Germany) and alcian blue (15 mg, Merck, Germany). Then, samples were dehydrated in ethanol (95%) for 3 days. After that, viscera was removed from samples and then samples were stained and macerated for 1 day in alizarin red-s (0.002%)/KOH (0.2%). Finally, samples were cleaned in glycerin /H₂O solutions (Merck, Germany) of increasing concentrations (25 , 50 , and 75) of glycerin for 7 days each, to 100% glycerin for storage. For 8-10 days old embryos, similar procedure was used but samples were stained and macerated for 1 day in alizarin red-s (0.002%)/KOH (0.5%). For 11-12 days old embryos, all stages were similar but alizarin red-s (0.002%)/KOH (1%) were used for staining. Finally, for 13 to next days old embryos, all stages were similar but 2 days administration of alizarin red-s (0.002%)/KOH (1%) were used for staining [16-18]. Finally, Various parts of thorax, including thoracic vertebrae, ribs, and sternum, were examined and photographed under a stereomicroscope (ZMZ1, Nikon, Thailand).

Results

Time of observation of thorax bone

The current research was performed to study the thorax ossification centers in partridge embryo by double staining alizarin red and alcian blue techniques. Table 1 shows the time of observing thorax bones and their various structures in the staining.

Table 2 represents the statistical analysis of data recovered from the experiment. Non-parametric Chi-square test was used for statistical analysis of data and days of ossification was considered as an important index. Findings revealed that absence of osteogenesis was found in majority of samples up to 15th day. Samples were reached to progressive procedure of osteogenesis from days 16 to 18. Process of osteogenesis was significantly increased from days 18 to 25. Significant statistical differences were obtained for all days of the experiment between stages of osteogenesis.

TABLE 1. The time of observing thorax bones and their various structures in the staining.

Bone	D*8	D9	D 10	D 11	D 12	D 13	D 14	D 15	D 16	D 17	D 18	D 19	D 20	D 21	D 22	D 23	D 24	D 25
Thoracic vertebrae	-	-	-	-	-	-	-	-	-	-	-	-	-	-	-	-	+	+
Notarium	-	-	-	-	-	-	-	-	-	-	-	±	±	±	+	+	+	+
Vertebral rib	-	-	-	-	-	-	-	-	±	-++	+	+	+	+	+	+	+	+
Sternal rib	-	-	-	-	-	-	-	-	-	-	-	-	±	+	+	+	+	+
Uncinate process	-	-	-	-	-	-	-	-	-	-	-	-	-	-	-	±	±	±
Body of sternum	-	-	-	-	-	-	-	-	-	-	-	-	-	-	-	±	±	±
Caudo-lateral process of sternum (Medial Pro.)	-	-	-	-	-	-	-	-	-	-	-	-	±	±	±	+	+	+
Caudo-lateral process of sternum (Lateral Pro.)	-	-	-	-	-	-	-	-	-	-	-	-	-	±	±	±	+	+
Cranio-lateral process of sternum	-	-	-	-	-	-	-	-	-	-	-	-	-	-	±	+	+	+
Keel	-	-	-	-	-	-	-	-	-	-	-	-	-	-	-	-	-	-

*Day +, Process of osteogenesis - , Absent of osteogenesis.

±, Progressive procedure of osteogenesis.

TABLE 2. Statistical analysis of data recovered from the experiment.

Days	Types			X ²	P value		
	A	B	C				
Day 8	30 (100.00%)	0 (0.00%)	0 (0.00%)	337.72	0.0		
Day 9	30 (100.00%)	0 (0.00%)	0 (0.00%)				
Day 10	30 (100.00%)	0 (0.00%)	0 (0.00%)				
Day 11	30 (100.00%)	0 (0.00%)	0 (0.00%)				
Day 12	30 (100.00%)	0 (0.00%)	0 (0.00%)				
Day 13	30 (100.00%)	0 (0.00%)	0 (0.00%)				
Day 14	30 (100.00%)	0 (0.00%)	0 (0.00%)				
Day 15	30 (100.00%)	0 (0.00%)	0 (0.00%)				
Day 16	27 (90.00%)	3 (10.00%)	0 (0.00%)				
Day 17	27 (90.00%)	3 (10.00%)	0 (0.00%)				
Day 18	27 (90.00%)	0 (0.00%)	3 (10.00%)				
Day 19	24 (80.00%)	3 (10.00%)	3 (10.00%)				
Day 20	18 (60.00%)	9 (30.00%)	3 (10.00%)				
Day 21	18 (60.00%)	6 (20.00%)	6 (20.00%)				
Day 22	15 (50.00%)	6 (20.00%)	9 (30.00%)				
Day 23	6 (20.00%)	6 (20.00%)	18 (60.00%)				
Day 24	3 (10.00%)	6 (20.00%)	21 (70.00%)				
Day 25	3 (10.00%)	6 (20.00%)	21 (70.00%)				
Total	408 75.60%	48 8.90%	84 15.60%				

A. Absent of osteogenesis

B. Progressive procedure of osteogenesis

C. Process of osteogenesis

Examination of the partridge embryos from day 8 to 13

Figure 1 represents the stained views of the partridge embryo from day 8 to 13.

Findings revealed that cartilaginous vertebral column were formed in the embryos on the 8th day (Fig. 1A). On the 9th day of embryo, the vertebral column became cartilaginous, and cartilage density increased from anterior to posterior vertebral column. Thoracic vertebrae were also formed and visible on the same day (Fig. 1B). The vertebral column and the thoracic vertebrae were completely cartilaginous on the 10th day of embryos. The vertebral column body and arch were visible, along with five or six thoracic ribs and the trace of the 6th rib. The sternal part of the ribs is cartilaginous, and the sternum began to form (Fig. 1C). On the 11th day, cartilaginous, completely separate thoracic vertebrae were seen in the embryo. Thoracic ribs had cartilaginous vertebral and sternal parts were also visible. The head and tubercle of the ribs were visible clearly, and the sternum was turned into cartilage (Fig. 1D). The thoracic vertebrae were still separated in the embryo on day 12. The vertebral and sternal parts of all thoracic ribs were seen as cartilaginous. Cartilaginous cranio-lateral and caudo-lateral processes of sternum could be seen on the same day (Fig. 1E). On the 13th day of embryo, the first four thoracic ribs had the uncinat process. The body of sternum, cranial border, and part of keel ventral edge were cartilaginous. Both medial and lateral parts of the caudo-lateral process were also cartilaginous and only the distal part did not turn into cartilage (Fig. 1F).

Examination of the partridge embryos from day 14 to 19

Figure 2 reveals the stained views of the partridge embryo from day 14 to 19.

On the 14th day of embryo, properties were the same as those of the 13th day, with only an increase in the cartilage density. The vertebral and sternal parts of the ribs were connected through cartilages (Fig. 2G). In the embryos of the 15th day, the last rib was a pseudo rib and the cranial border of sternum was not cartilaginous (Fig. 2H). On the 16th day of embryo, spinous process of the last cervical vertebrae and the first three thoracic vertebrae became relatively wide and the distance between them is was less than the previous and next vertebra. The body of ribs began to become transparent at the top of uncinat process junction, showed, it was at the ossification stages. The keel completely turned into cartilage (Fig. 2I). On the 17th day of embryo, the spinous processes of the last cervical vertebra and the first three thoracic vertebrae are seen as completely long and wide as interconnecting cartilages forming a notarium. The 6th rib was seen as a pseudo rib and in one case as floating. The ventral crest of the last cervical vertebra and first three thoracic vertebrae associated with the notarium grew and attached to each other were also seen. The ossification process of the medial part of vertebral ribs increased at the uncinat process junction (Fig. 2J). On the 18th day of embryo, the body of rib above the uncinat process was stained by the color of alizarin red and began to ossify. The body and processes of the sternum and keel were completely cartilaginous (Fig. 2K). The ventral crest of the notarium was transparent and the process of ossification began on the 19th day of embryo. Vertebral ribs had further ossification and reached close to the neck of ribs (Fig. 2L).

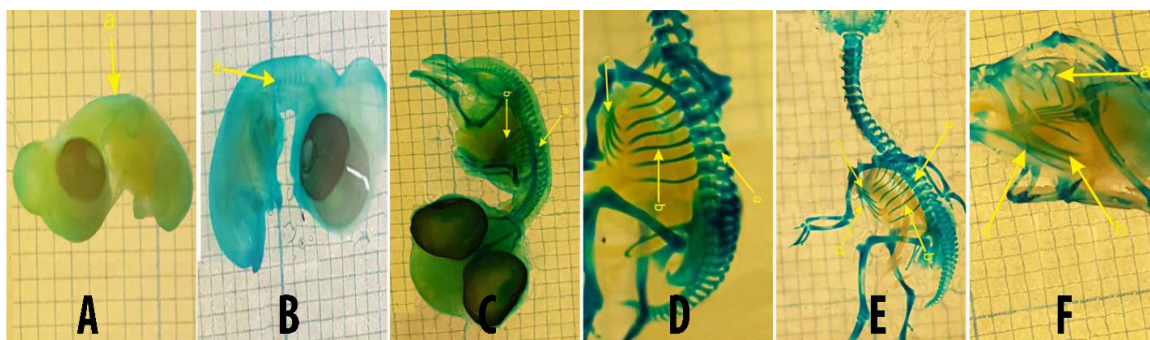


Fig. 1. The stained views of the partridge embryo from day 8 to 13.

1A) Lateral View at Day 8. (a) Thoracic Vertebrae; 1B) Lateral View at Day 9. (a) Vertebral Column; 1C) Lateral View at Day 10. (a) Thoracic Vertebrae (b) Rib; 1D) Lateral View at Day 11. (a) Thoracic Vertebrae (b) Rib; 1E) Lateral View at Day 12. (a) Thoracic Vertebrae (b) Rib (c) Cranio-lateral Process(d) Caudo-lateral Process; 1F) Lateral View on Day 13. (a) Uncinat process (b) Body of Sternum (c) Keel.

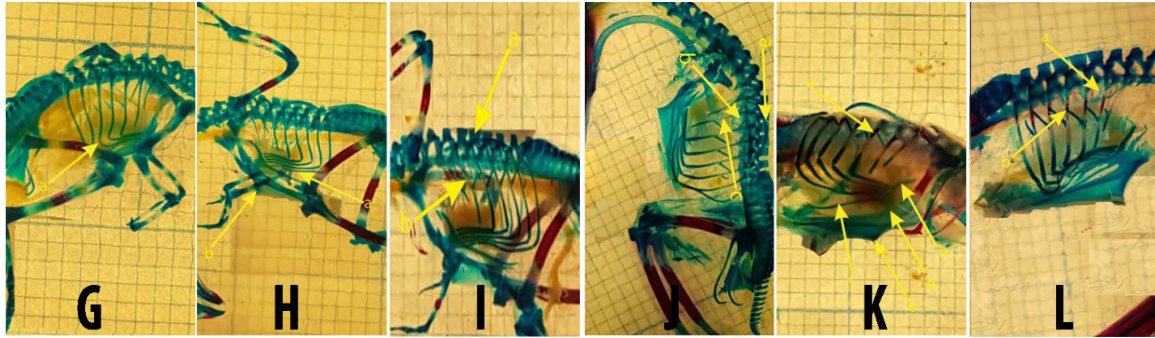


Fig.2. The stained views of the partridge embryos from day 14 to 19.

2G) Lateral View on Day 14. (a) Rib; 2H) Lateral View on Day 15. (a) Rib, (b) Keel; 2I) Lateral View on Day 16. (a) Rib, (b) Keel; 2J) Lateral View on Day 17. (a) Spinous Process (b), Ventral Crest, (c) Rib; 2K) Lateral View on Week Day 18. (a) Rib, (b) Cranio-lateral Process, (c) Caudo-lateral Process (d) Body of Sternum, (e) Keel; 2L) Lateral View on Day 19. (a) Ventral Crest, (b) Rib.

Examination of the partridge embryos from day 20 to 25

Figure 3 reveals the stained view of the partridge embryo from day 20 to 25.

On day 20, ventral crest of the notarium showed a more advanced ossification process in the embryo. The medial part of sternal ribs began to become transparent from the cranial to the caudal, indicating the onset of ossification. The sternal part of rib No. 5 was completely cartilaginous. Transparent status started in the proximal part of the medial caudo-lateral process was seen (Fig.3M). On the 21th day of embryos, the medial parts of the 2nd, 3rd, and 4th sternal thoracic ribs were slightly reddish and were in the process of ossification. The 5th rib was still cartilaginous. The distal and proximal parts of the sternal ribs were still cartilaginous. The proximal part of the lateral caudo-lateral process was also transparent (Fig.3N). On day 22, the ventral crest of the notarium was ossified at the junction with the body of vertebrae in the embryo. The ossification was also observed in the head and tubercle of ribs. The process of ossification was progressive in the ribs. The cranio-lateral process was transparent and began the process of ossification, with only the head remaining cartilaginous. A cartilaginous manubrium was still visible (Fig.3O). On the 23th day of embryo, the spinal processes of the last cervical vertebra and the first three thoracic vertebrae were seen as cartilaginous and connected to each other in their heads. In one sample, the uncinat process of the first thoracic rib was transparent and started the

process of ossification. The body of sternum was transparent at the cranio-lateral and caudo-lateral junction. There was an ossified cranio-lateral process with only a free distal cartilaginous section. The medial part of the caudo-lateral process was visible at the ossified junction and the free distal cartilaginous section (Fig.3Q, P). On the 24th day, the vertebral body and arches of thoracic vertebra were completely ossified in the embryo. The cranial to the caudal uncinat processes of vertebra showed the procedure of ossification. The ossification was visible in medial and lateral parts of the caudo-lateral process, with the latter being slightly cartilaginous (Fig.3R). The vertebral and sternal ribs were ossified and only the junctions of these parts were cartilaginous on the 25th day of embryo. The manubrium was transparent and showed the onset of ossification process (Fig.3S). Fig.4 signifies the procedure of osteogenesis.

Discussion

Skeletal staining is an imperative part of anatomical researches which can assess macroscopic disorders and also procedure of skeletal development in cartilages and bones. Its application in embryonic and post-delivery periods is also critical stage in teratological surveys. In keeping with this, typical and atypical developing researches on poultry embryo system are compulsory, as the extensive application of poultry embryo model in embryological and teratological examinations [19].

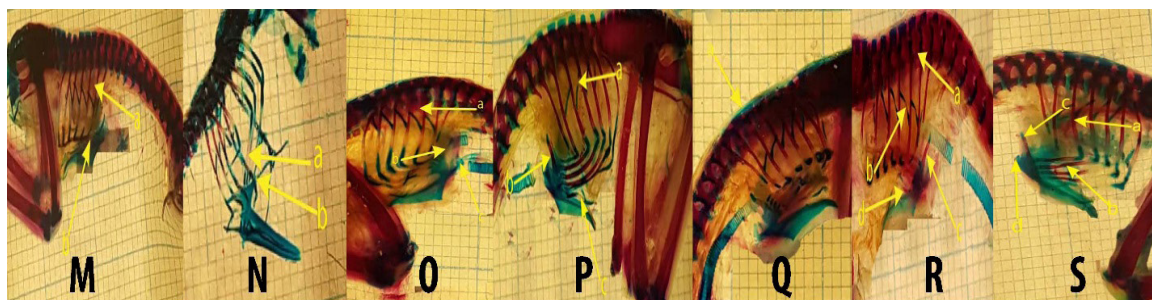


Fig.3. The stained view of the partridge embryos from day 20 to 25.

3M) Lateral View on Day 20. (a) Ventral Crest, (b) Sternal Rib; 3N) Lateral View on Day 21. (a) Sternal Rib, (b) Caudo-lateral Process; 3O) Lateral View on Day 22. (a) Ventral Crest, (b) Cranio-lateral Process, (c) Manubrium; 3P) Lateral View on Day 23. (a) Spinous Process; 3Q) Lateral View on Day 23. (a) Uncinate Process, (b) Cranio-lateral Process (c) Caudo-lateral Process; 3R) Lateral View at Day 24. (a) Thoracic Vertebrae, (b) Uncinate Process, (c) Cranio-lateral Process, (d) Caudo-lateral Process; 3S) Lateral View on Day 25. (a) Vertebral Rib, (b) Sternal Rib, (c) Cranio-lateral Process, (d) Manubrium.

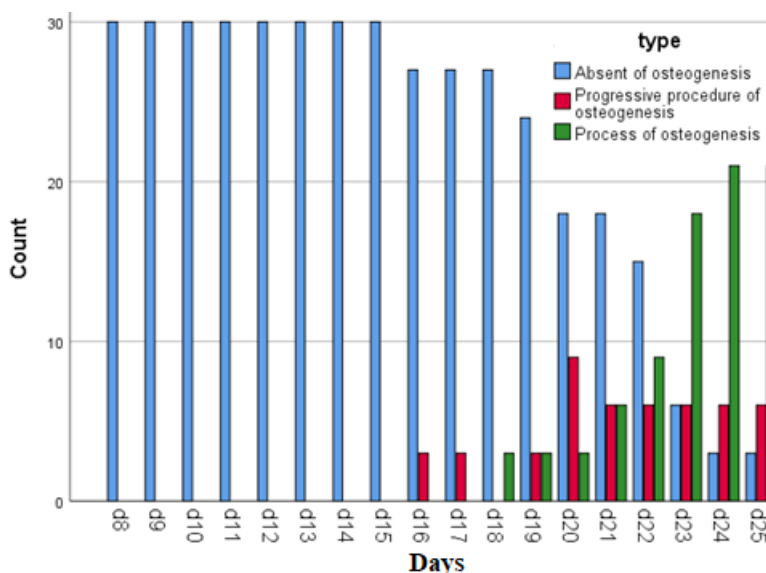


Fig.4. Procedure of osteogenesis among days of the experiment.

Despite the importance of thorax in respiration and much energy spent for flight in flying birds with high levels of metabolism, there are relatively rare researches on ossification centers and the ossification process of the skeleton and thoracic bones. The present research was the first report of development assessment of the thorax ossification centers in partridge embryos by double staining alizarin red and alcian blue techniques. Findings revealed that cartilaginous thoracic vertebrae were formed on the 8th day. Cartilaginous ribs were formed in the 9th day of embryo. A cartilaginous sternum began to form on the 10th day of embryo. Finally, on the 25th day, the cranio-medial process

of sternum was the first ossification center in the embryos.

Scarce investigations were conducted in this field. First of all, Hogg [20] conducted a survey on chicken to examine ossification centers. He revealed that there were two ossification centers in thoracic vertebrae, one in the vertebral arch and the other in the vertebral body. In the ribs, two ossification centers appeared separately in the vertebral and sternal ribs. Ossification centers in the uncinat processes emerged at hatching time. There are five ossification centers in the sternum, one in the body and two on each side

of the cranio-lateral and caudo-lateral processes [20]. Retnoaji, Wulandari, Nurhidayat and Daryono [21] reported that ossification in chicken embryos started in the skull at the 10th day of incubation, and the first ossification centers in the vertebrae and long bones appeared from the 18th day of incubation. Firdous, Maya, Massarat and Baba [5] evaluated the ossification stages of axial and appendicular skeletons in 78 duck embryos from the 3rd and the 28th days of incubation, respectively. It was reported that the ossification process started from the 17th and the 11th days of incubation in thoracic vertebrae and the body of ribs, respectively. However, the growth of which was not complete until the last day of incubation. The uncinat processes also remained cartilaginous [5]. In comparison with our findings, the ossification centers appear earlier in the duck embryo than that of partridge, but ossification in some bones (e.g., uncinat processes) of partridge begins from the 23rd day of incubation. Pourlis and Antonopoulos [4] observed ossification centers in thoracic vertebrae on the 10th and 11th days of incubation of Japanese quail. Additionally, they reported that true ribs began to ossify on the 7th day of incubation. Ossification in uncinat processes started on day 15 of incubation of Japanese quail. Caudo-lateral and cranio-lateral processes showed ossification on days 13 and 14 of incubation, respectively. The body of sternum and keel began to ossify after hatching of Japanese quail [4]. Although changes occur in bone mesenchymal density, primary cartilage, and thoracic ossification at different times, but it is clearly seen that the evolutionary development of thoracic skeleton in the partridge embryo is very similar to those of the quail and chicken embryos. A comparison of thoracic ossification process in the embryos of quails and chickens clearly indicate that the skeletal elements are in a very similar sequence in all the three birds. Although the evolutionary growth in the partridge is longer than in chickens and in chickens longer than in quails, the final shape of the thorax is similar in all the three birds. Based on observations of thorax growth, it seems that partridges, chickens, and quails are properly classified in the order Galliformes [22].

Conclusion

To the best of our knowledge, the present study is the first report of the developmental study of the thorax ossification centers and related structures in partridge embryo using alizarin

red and alcian blue double staining techniques. Findings revealed that alizarin red and alcian blue double staining techniques can effectively determine the development procedure of thorax ossification centers in partridge embryos. The emergence of ossification centers in diverse parts of thorax and the developmental process were not observed at the pre-hatching time. Furthermore, the ossification process and formation of all thoracic bones were completed after hatching. However, further investigations are required to assess other embryonic properties of thorax ossification centers in embryos of partridge and other poultry species.

Acknowledgements

Authors would like to thank from the staffs of the research deputy of Islamic Azad University, Science and Research Branch, Tehran, Iran.

Conflict of interest

Authors declared that they have no conflict of interest.

Funds statement

Funding is not applicable.

References

1. Antunes, I., Coimbra, M., Ribeiro, A., Ferreira, J., Dos Santos, F.A., Alves, S., Bessa, R. and Quaresma, M., Nutritional value of meat lipid fraction from red-legged partridge (*Alectoris rufa*) obtained from wild and farmed specimens, *Poultry Science*, **98**(2), 1037-1046 (2019).
2. Hirasawa, T. and Kuratani, S., Evolution of the vertebrate skeleton, morphology, embryology, and development, *Zoo. Letters.*, **1**(1), 1-17 (2015). DOI 10.1186/s40851-014-0007-7
3. Thorp, B.H., Skeletal disorders in the fowl, a review, *Avian Pathology*, **23**(2), 203-236 (1994).
4. Pourlis, A. and Antonopoulos, J., The ossification of the vertebral column, thorax and sternum in the quail (*Coturnix coturnix japonica*), *Vet. Res. Forum.*, **10**(1), 1-7 (2019).
5. Firdous, A., Maya, S., Massarat, K. and Baba, M., Developmental ossification sequences of the appendicular and axial skeleton in Kuttanad duck embryos (*Anas platyrhynchos domesticus*), *Open. Vet. J.*, **6**(1), 1-5 (2016).
6. Sawad, A., Hana, B.A. and Al-Silawi, A.N., Morphological study of the skeleton development in chick embryo (*Gallus domesticus*), *Int. J. Poul. Sci.*, **8**, 710-714 (2009).

7. Atalgin, S. and Kürtül, I., A morphological study of skeletal development in turkey during the pre-hatching stage, *Anatomia, Histologia, Embryologia*, **38**(1), 23-30 (2009).
8. Wang, M., O'Connor, J.K., Bailleul, A.M. and Li, Z., Evolution and distribution of medullary bone, evidence from a new Early Cretaceous enantiornithine bird, *National. Sci. Rev.*, **7**(6), 1068-1078 (2020).
9. Ahmad, B., Nabi, G., Hayat, M. and Muhammad, J., Habitat study of Chukar partridge (*Alectoris chukar*) in district Malakand, A case study of town Thana, Pakistan, *J. Bio. Env. Sci.*, **11**(4), 11-17 (2017).
10. Dial, K.P., Randall, R.J. and Dial, T.R., What use is half a wing in the ecology and evolution of birds?, *BioScience.*, **56**(5), 437-445 (2006).
11. Pis, T., Growth and development of chicks of two species of partridge, the Grey partridge (*Perdix perdix*) and the chukar (*Alectoris chukar*), *British. Poult. Sci.*, **53**(1), 141-144 (2012).
12. Haydarian, S., Pousty, I., Gilanpour, H. and Mortazavi, P., Histogenesis study on prenatal development of the spleen and thymus of partridge (*alectoris chukar*), *Saussura.*, **3**(1), 363-369
13. Hashemnia, S., Shojaei, B. and Razavi, H., Liver Histogenesis in Chukar Partridge (*Alectoris Chukar*) Embryo, *Anatomical. Sci.*, **12**(3), 129-135 (2015).
14. Shojaei, B., Hashemnia, S. and Rad, R.E., Histochemical study of the oesophagus in the chukar partridge (*Alectoris chukar*) embryo, *Folia. Morphologica.*, **75**(4), 474-480 (2016).
15. Mir, T., Shojaei, B. and Hashemnia, S., Histomorphogenesis of the Chukar Partridge (*Alectoris Chukar*) Knee Joint, *Anatomical. Sci. J.*, **12**(2), 61-67 (2015).
16. Ojeda, J., Selective skeletal staining in whole chicken embryos, a rapid alcian blue technique, *Stain. Technol.*, **45**, 137-138 (1970).
17. Watson, A., In toto alcian blue staining of the cartilaginous skeleton in mammalian embryo, *Anat. Rec.*, **187**, 743 pages 657-669 (1977).
18. Tsudzuki, M. and Wakasugi, N., Genetic Head-Skeleton Abnormalities in the ET (ear tuft) Strain of Japanese Quail, *Japanese. Poultry. Sci.*, **25**(4), 207-217 (1988).
19. Alfonso-Torres, K., Gargaglioni, L., Pizauro, J., Faria Filho, D., Furlan, R.L. and Macari, M., Breeder age and bone development in broiler chicken embryos, *Arquivo Brasileiro de Medicina Veterinária e Zootecnia*, **61**(1), 219-226 (2009).
20. Hogg, D., A re-investigation of the centres of ossification in the avian skeleton at and after hatching, *J. Anatomy.*, **130**(4), 725-743 (1980).
21. Retnoaji, B., Wulandari, R., Nurhidayat, L. and Daryono, B., Osteogenesis study of hybrids of Indonesia's native chicken Pelung (*Gallus gallus domesticus*) with Broiler (*Gallus gallus domesticus*), *Asian. J. Anim. Vet. Adv.*, **11**(8), 498-504 (2016).
22. Wetmore, A., A revised classification for the birds of the world, *Smithson. Misc. Collns.*, **117**, 1-22 (1951).